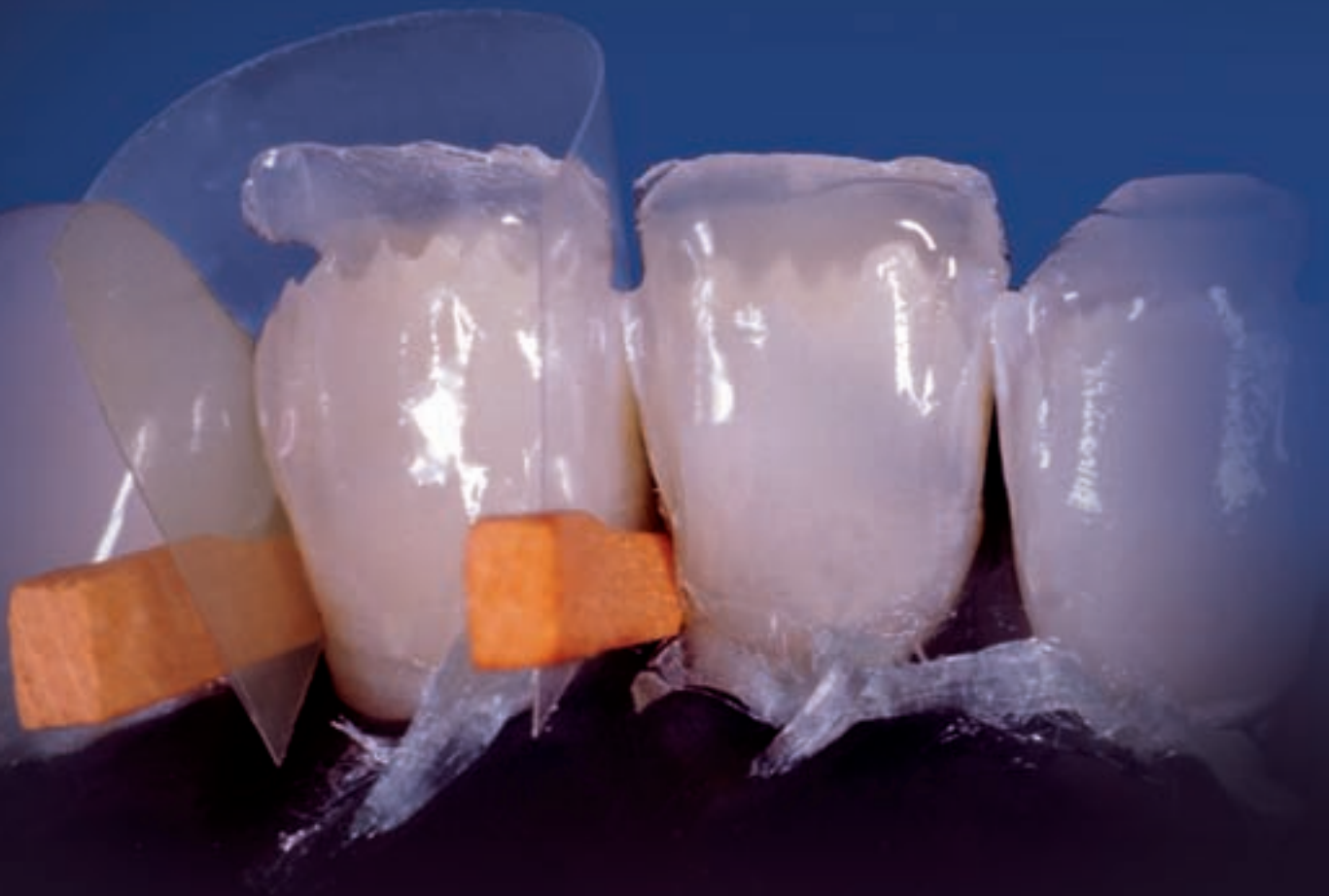

REFLECT

d e n t a l p e o p l e f o r d e n t a l p e o p l e 0 1 / 0 9



Predictable results

Restoration of an upper central incisor

Cementation – a decisive factor

Cementation – one of the most sensitive working steps

Material combination in post build-ups

A case study on the combination of metal and ceramic materials

Editorial

Dear Reader



The year 2009 is expected to be one of the most difficult ones in the past sixty years. However, we do not want to dwell on forecasts and theoretical arguments. We would rather concentrate our efforts on presenting an advanced product range which

responds to the aesthetic, functional and economic needs of our customers.

We are proud to present a series of exciting new products and coordinated treatment systems which are in line with the latest trends in dental medicine and dental laboratory technology. In this issue of Reflect we would like to give you a preview of the products which we will be launching at IDS 2009 in Cologne.

The following pages include an interesting case study in which metal and ceramics have been combined to build up a post. In addition, this issue contains an item on the new highly translucent IPS e.max material (HT). The contents of this publication are rounded off by an article on the topic of metal-ceramics as well as the story behind the development of the new Phonares tooth line.

We are well-equipped to accept the challenges of the future. We hope that this issue of Reflect gives you much reading pleasure and we invite you to come and pay us a visit at our booth at IDS 2009 in Cologne.

Warmest regards

Norbert Wild
Manager
Ivoclar Vivadent GmbH Germany

Cover: Build-up of a lower anterior restoration

Mamelon-like structures have been incorporated into the existing dental hard tissue to ensure a smooth transition.

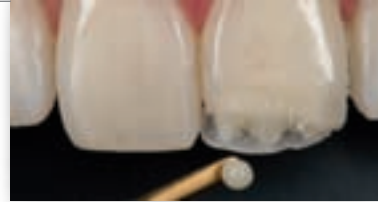Turn to page 15 to read more about this topic in the article by Prof Dr Daniel Edelhoff and DT Oliver Brix.

Editorial

- Outlook for 2009* 02
Norbert Wild (D)

Dental medicine

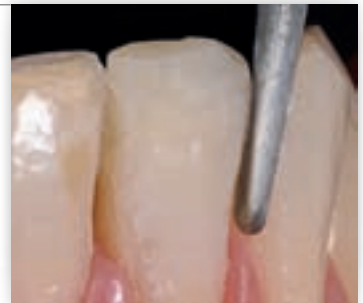- Predictable results* 04
Dr Carlos Fernández Villares (E)



04

- Cementation – a decisive factor* 07
Dr Sandro Pradella (I)

- Shade, form and function* 10
Ulf Krueger-Janson, Dentist (D)

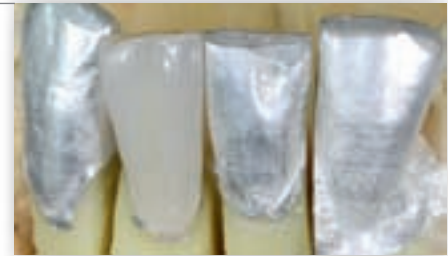

10

Teamwork

- Material combination in post build-ups* 12
DDr Marlies Moser
and Christoph Zobler, MDT (A)

- Composite meets all-ceramic* 15
Prof Dr Daniel Edelhoff and Oliver Brix, DT (D)

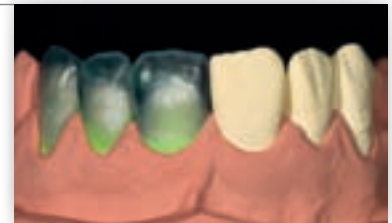


12

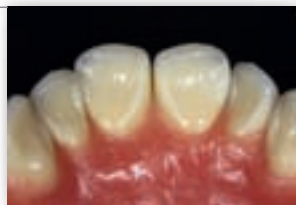Dental technology

- Teaming up for the future* 18
Volker Brosch, MDT (D)

- A new generation of denture teeth* 21
Thorsten Michel, MDT (D)



18



21

PUBLISHER'S CORNER

| | | | |
|-------------------|--|------------------|--|
| Publisher | Ivoclar Vivadent AG Bendererstr. 2 9494 Schaan / Liechtenstein Tel +423/2 35 35 35 Fax +423/2 35 33 60 | Coordination | Karin Böhler Tel +423 / 2 35 35 03 karin.boehler@ivoclarvivadent.com |
| Publication | 3 times a year | Editorial office | K Böhler, Dr R May, N van Oers, T Schaffner, |
| Total circulation | 80,000 (Languages: German, English, French, Italian, Spanish) | Reader service | karin.boehler@ivoclarvivadent.com |
| | | Production | teamwork media GmbH, Fuchstal/Germany |

Predictable results

Restoration of an upper central incisor

Dr Carlos Fernández Villares, Madrid/Spain

The delivery of predictable results continues to be an important objective in restorative dentistry. Today, the restoration of teeth with composite filling materials ranks among the standard procedures applied by dental professionals on a daily basis. Hence we ought to have a profound knowledge of the handling and processing of dental composite, as achieving dependable, reproducible results with uncomplicated techniques is essential to building a successful practice. In order to attain natural-looking outcomes with less effort, the clinician must have a comprehensive knowledge of the properties of the individual components of a restorative system and a thorough understanding of their application in the restorative process.

A wide variety of composite restorative systems are available on the market today. Given this wide range of options, it can be difficult sometimes to make the right choice. Consequently, there is one question that keeps surfacing in many discussion forums for restorative dentists: Is there a system that is suitable for all types of restorations? In order to answer this question conclusively, we must first know exactly what the characteristics of the individual products are and, even more importantly, how the respective products should be applied. There is no single solution that works for every restorative case, because every tooth is different. We have to make use of our visual ability to perceive the optical and structural differences between the individual teeth and gain a clear picture of what we would like to reproduce.

Among the different anterior restorations, Class IV restorations in upper central incisors clearly represent the biggest challenge. The shade and shape of the fractured piece need to be faithfully mimicked in order to restore the tooth to its original condition (Fig 1).

A comprehensive diagnostic evaluation and the formulation of a dental treatment plan is imperative to success-

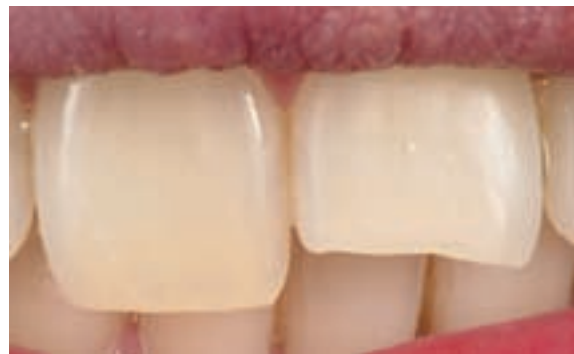
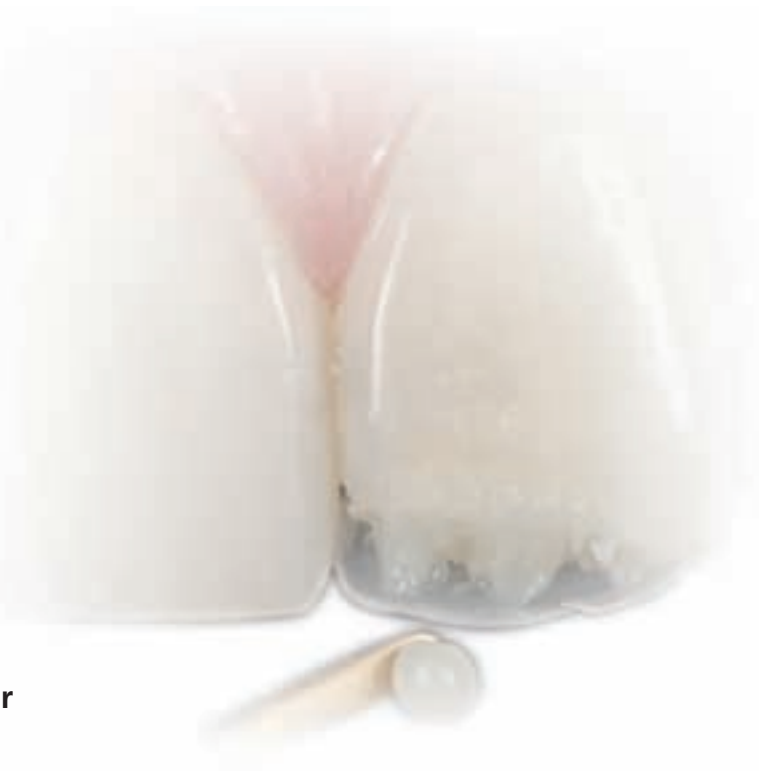
Fig 1 The central incisor in need of restoration

fully conduct dental restorative procedures and achieve predictable results. During the first appointment photos are made and alginate impressions are taken to record the pre-operative situation. Subsequently, a diagnostic wax-up is created. Based on the photos, a treatment guideline is established, to which the dental professional may refer at any time during the treatment procedure. The clinical treatment time is considerably reduced by proceeding in this way (Fig 2). The same applies to the use of a wax-up, which provides information on all the essential details that need to be reproduced. Moreover, a silicone matrix can be fabricated from the wax-up, which represents an invaluable aid in the fabrication of tooth restorations with composite resin (Fig 3).

Before starting the restorative procedure, a rubber dam should be placed. Optionally, a lip and cheek retractor (e.g. OptraGate®) can be inserted, which reliably retracts the lips and cheeks during the treatment procedure and thus facilitates the work of the dentist (Fig 4).

The first step in the procedure was the preparation of the tooth. The literature on this subject (Fahl 2000, Vanini 2003, Baratieri 2008) shows that there is a wide variety of preparation designs to choose from. In the case in question, we decided to use a circular mini bevel, in order

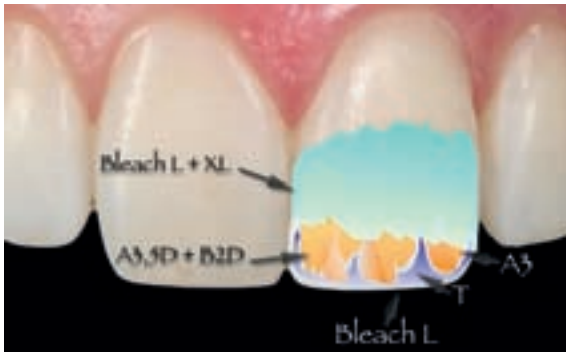

Fig 2 Layering diagram for Tetric EvoCeram

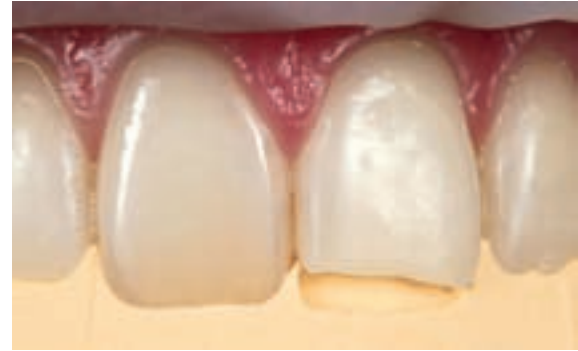

Fig 3 The use of a silicone matrix simplifies the treatment procedure.

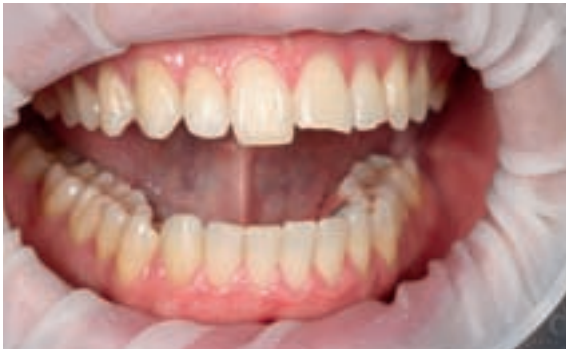

Fig 4 OptraGate

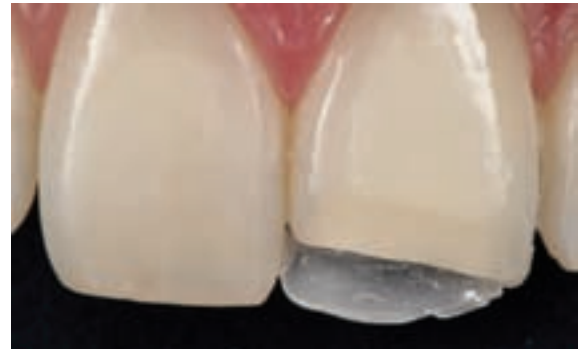

Fig 5 Layering of shade Bleach L

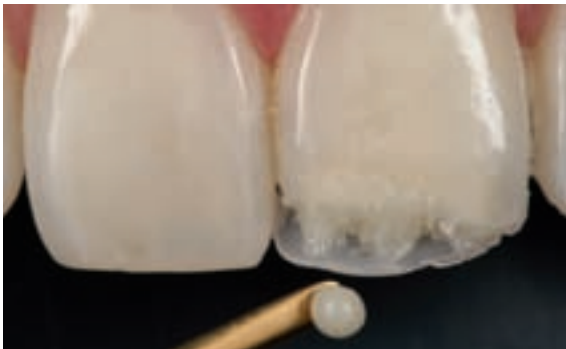

Fig 6 Tetric EvoCeram A3.5 Dentin, B2 Dentin and A3 Enamel

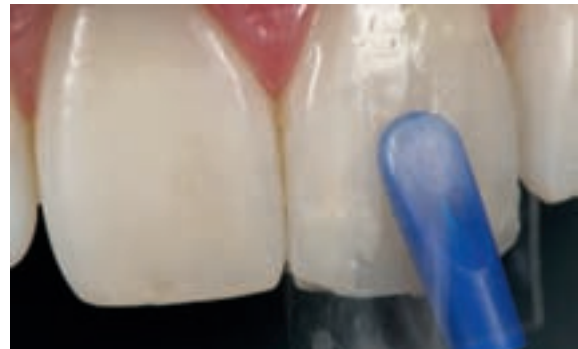

Fig 7 Bleach L/XL

to achieve an improved optical appearance and ensure a seamless integration of the restoration into the oral environment. Next, the cavity surfaces were etched with etchant gel and an adhesive of the 5th generation (ExcITE[®]) was applied. ExcITE is a non-coloured, filled adhesive which is capable of withstanding the masticatory forces. This was followed by composite placement, whereby in this case shade Bleach L was used to build up the palatal wall (Fig 5). By using this shade, a higher degree of brightness can be achieved. Each increment was individually light-cured according to the instructions of the manufacturer using an LED curing light. In this way, optimum support of the overlying composite layer was ensured. Subsequently, the silicone matrix was removed carefully, in order not to damage the thin, palatal wall. Next, we started to work on the fracture line. An opaque layer needed to be applied along the line of fracture so that the transition between the natural tooth and the restoration was reliably masked. This ensured that the pas-

sage of light was undisturbed in this area. In the case presented, we used a mixture of A3.5 Dentin and B2 Dentin for this purpose. The material was applied in the incisal region. At the same time it was used to build up the mamelons. The previously conducted analysis had shown that three mamelons had to be created (Fig 6). Shade A3 Enamel was used to build the dentin layer as well as part of the mamelons. In a next step, a second increment of Bleach L was placed to create an opalescent halo around the incisal edge (Fig 7).

The desired degree of translucency was achieved by means of the Incisal shade T. Due to its greyish colour and high translucency, it allows the typical characteristics of young patients' incisal edges to be faithfully mimicked. For the final enamel layer that enveloped the entire restoration, a mixture of Bleach L and Bleach XL was used. It was applied in a very thin layer – thinner than the natural enamel layer. Particular emphasis was placed on achieving optimum brightness, which was adjusted by means of

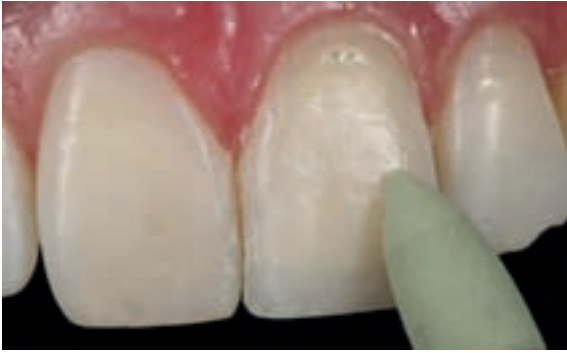

Fig 8 Polishing with Astrobrush

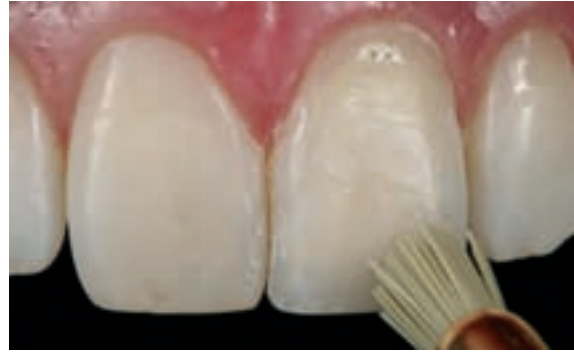
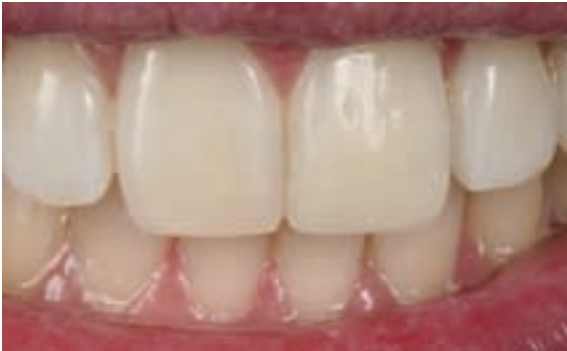
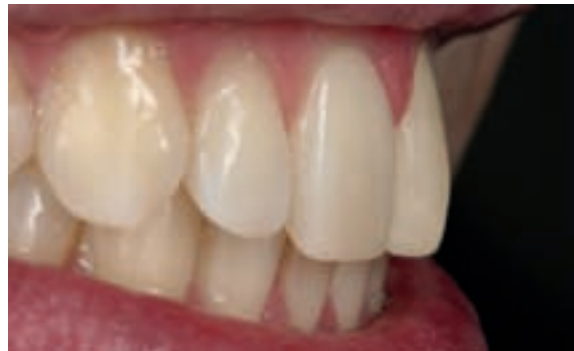Fig 9 Final contouring and high-gloss polishing with Astrobrush



Figs 10 and 11 Final result



the amount of Bleach XL used. The Bleach shades, which were initially only intended for bleached teeth, can be used as enamel material in the reconstruction of just about any tooth. They allow the clinician to reliably adjust the brightness of the restoration. When using various shades and translucencies, it is of vital importance to know exactly how these materials tend to influence the translucency of a restoration.

After the application of the final covering layer and the light-curing of each increment up to 2 mm with a high-performance LED curing light (new bluephase®), the entire restoration was coated with glycerine gel prior to final light-curing. In this way a higher degree of polymerization was achieved.

As mentioned above, special emphasis had to be placed on two aspects in the fabrication of the restoration: the optical appearance (layering) and structural detail (surface texture). The latter was mainly incorporated during the finishing and polishing step.

Coarse finishing was performed using aluminium oxide-coated polishing discs. Fine finishing was accomplished with the finishing and polishing instruments of the Astropol® system at low speeds (Fig 8). For final contouring and the achievement of a natural-looking, high surface gloss, the Astrobrush polishing system was used. The

abrasive medium silicon carbide is integrated into the special fibres of these polishing brushes (Fig 9). The completed restoration blended seamlessly into the remaining dentition and was virtually invisible. Thus we were able to fully meet the patient's expectations. The final result increased our motivation to further optimize even very good restorative outcomes in the future (Figs 10 and 11).

Conclusion

In order to achieve successful results with composite restoratives, the fabrication of restorations should be practiced in advance. This should include the faithful reproduction of natural teeth using different materials. A profound knowledge of the tooth anatomy and good visual skills are crucial to achieving predictable results. □

Contact address:

Dr Carlos Fernández Villares
Mética Dental, C/Príncipe de
Vergara 276 1° G
28016 Madrid
Spain
fernandezvillares@hotmail.com



Cementation – a decisive factor

Cementation – one of the most sensitive working steps

Dr Sandro Pradella, Eremo di Curtatone/Italy

Reliable cementation of fixed prosthetic restorations represents one of the most sensitive and crucial tasks in the course of prosthetic dental treatment. Mistakes committed during this step may adversely affect the aesthetic appearance and service life of the restoration.

Against such a background, it is essential to have a thorough grasp of the chemical and physical properties of dental cements as well as of their range of indication and compatibility with appropriate restorative materials. Ideally, the luting material should provide a flawless and durable bond between the tooth structure and prosthetic reconstruction so that a resistant unit which cannot be penetrated by oral liquids is established.

Ease of use is another basic requirement of luting materials. Not all luting composites are easy to mix and apply. In addition, excess removal of composite-based cements in particular presents a clinical challenge.

This is a drawback compared to conventional luting materials. For this reason, many dentists prefer using conventional luting cements to place veneered aluminium, lithium disilicate and zirconium oxide restorations. However, practical experience has shown that the conventional method does not provide the same high-performance results as the adhesive method. Adhesive cementation methods are more complicated than non-adhesive ones, but they ensure an optimal bond, promoting a durable unit between the tooth structure and prosthetic restoration.

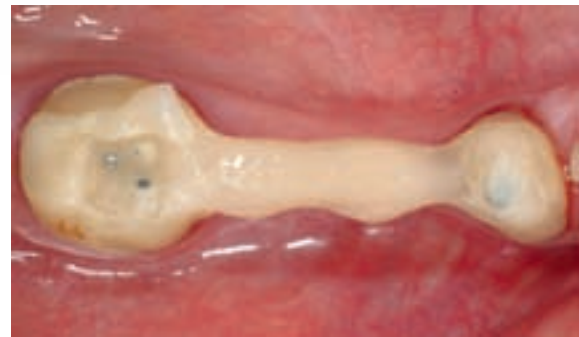

Fig 1 Occlusal view of bridge

Case study

A female patient hit her head on the pavement after a car ran into her. As she was not wearing a full face helmet, her jaw was unprotected. She suffered a jaw fracture and a fracture of posterior teeth, which had previously been restored with two bridges made of glass fibre-reinforced composite. Both bridges had to be replaced because of the accident. As the patient wanted her teeth to be restored aesthetically, a ceramic veneered zirconium oxide system was selected. These restorations can be cemented using either a conventional or adhesive method.

Only the glass fibre-reinforced composite bridge core was left of the original bridge in quadrant 4; the composite veneering material had completely delaminated from the framework (Fig 1). It was therefore necessary to fabricate a new bridge to restore the normal function of the jaw. The remaining part of the bridge had to be removed to prepare the abutment teeth for the new bridge. The abutment teeth had been restored with glass fibre posts and core build-ups ten years ago. At the time, both these reconstructions and the bridge proper were inserted using Variolink® II luting composite.

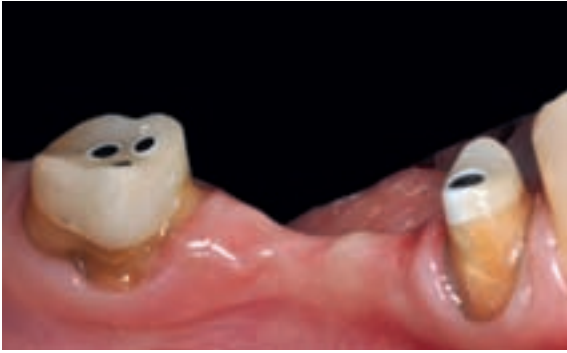

Fig 2 Lateral view of prepared abutment teeth

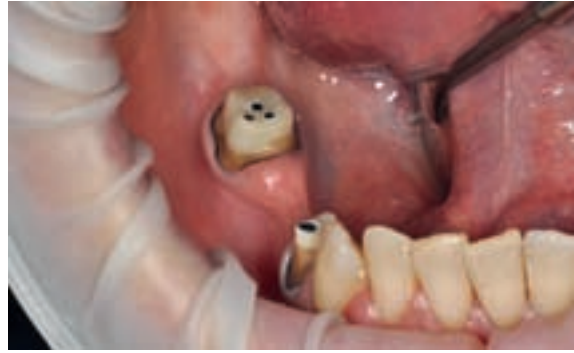

Fig 3 Relative isolation of the treatment field with OptraGate

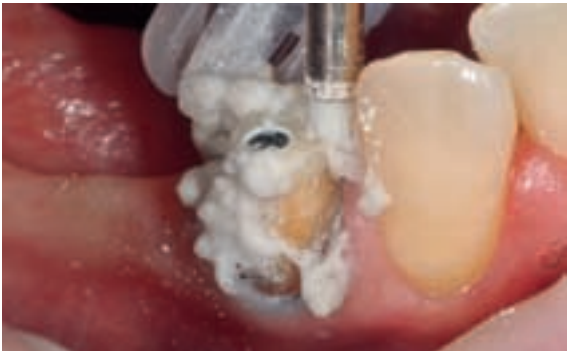


Fig 4 Cleaning of remaining tooth structure with water, pumice and soap

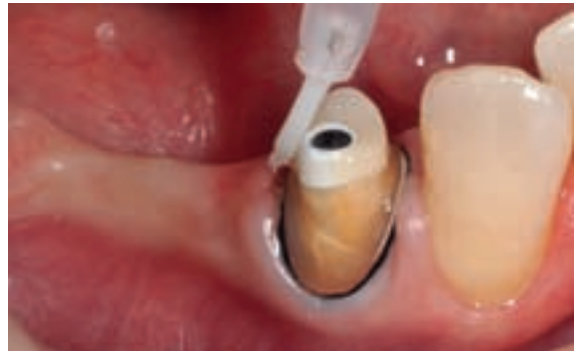

Fig 5 Application of adhesive

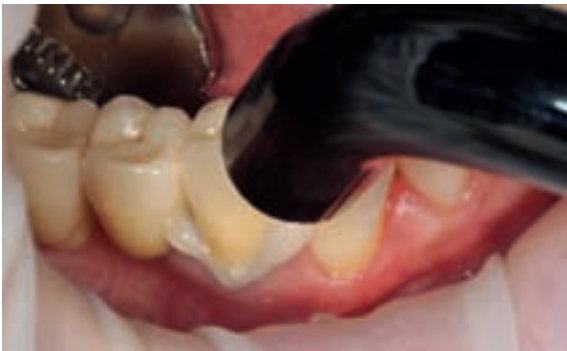

Fig 6 Light-curing of excess material

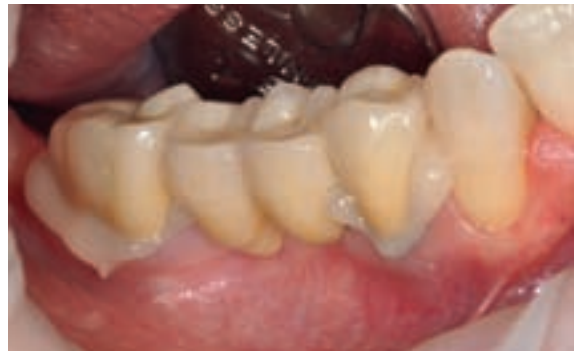

Fig 7 Bridge in situ with excess cement

The abutment teeth were completely intact and did not show any signs of infiltration or secondary caries when they were prepared (Fig 2). This attests to the quality and durability of the luting composite used. After tooth preparation, a zirconium oxide bridge was fabricated according to conventional procedures.

Prior to adhesive cementation, the contact surfaces of the zirconium oxide bridge were conditioned. For this purpose, Metal/Zirconia Primer was applied to the inner surfaces of the bridge. After a reaction time of three minutes, excess primer was dispersed to a thin layer using blown air. It is advisable to place an OptraGate® lip and cheek retractor before commencing oral treatment, as this auxiliary device enhances the view and ensures relative

isolation of the treatment field (Fig 3). It is also recommendable to place a retraction cord for sulcus fluid control to avoid contamination of the tooth surfaces with fluid.

At the beginning of the treatment, the entire surface of the remaining tooth structure was carefully cleaned using a mixture of water, pumice and liquid soap. In the process, any residual temporary luting material and other impurities, which might adversely affect the bonding result, were completely removed (Fig 4). The preparation surfaces were thoroughly cleaned with water, gently dried and the adhesive Multilink® Primer A/B was applied. This adhesive consists of two components A + B, which are mixed together (Fig 5). Multilink Primer A/B is a self-etching one-step system, which eliminates the

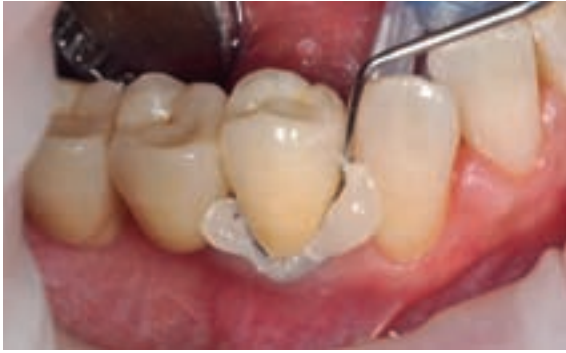

Fig 8 Easy removal of excess material

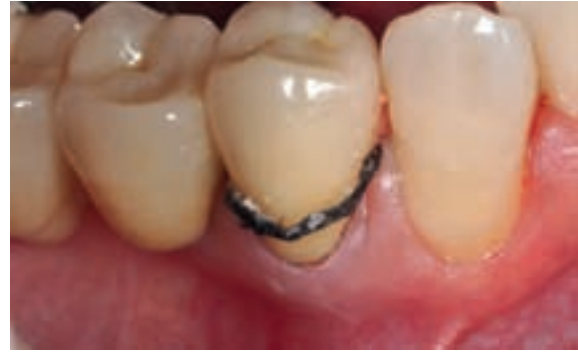

Fig 9 Removal of retraction cord placed for sulcus fluid control

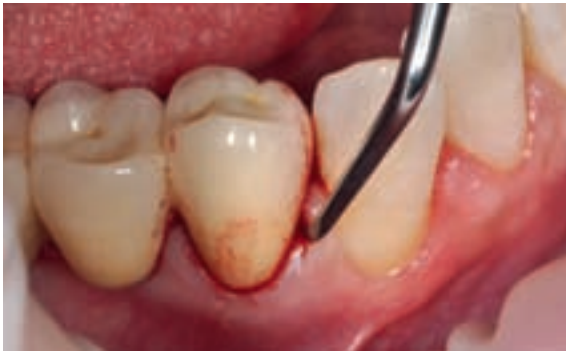

Fig 10 Removal of residual cement and adhesive with a curette

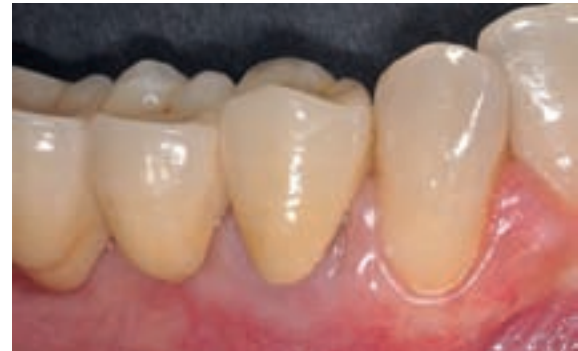

Fig 11 Lateral view of the bridge, two weeks after insertion

need for additional etching with phosphoric acid. After the primer, the dual-curing luting composite Multilink® Automix was applied. This material is supplied in an automix syringe containing both base and catalyst paste and does not require separate manual mixing. Whilst the material is extruded from the syringe, the two components are optimally mixed in the automix syringe tip, eliminating the risk of air entrapments. Multilink Automix can be dispensed directly onto the crown, which facilitates the working procedure and helps save time. Due to its optimal consistency, the material can be accurately applied to the area where needed without contaminating any other tooth surfaces. Excess material should be removed in a timely fashion, i.e. during the first phase of the curing process. Multilink Automix features an improved new "Easy Clean-Up" formula, which further facilitates excess removal and offers clear advantages in the clinical handling of the material. Excess cement is light-activated for approximately two seconds per quarter surface (eight seconds in total) using a curing light (Figs 6 and 7). In the process, the excess obtains a gel-like consistency and can be easily removed in one piece using a scaler (Fig 8).

At the end of the cementation process, the retraction cord, which was instrumental to fluid control, was removed (Fig 9). The preparation margins were checked

with a curette (Fig 10) to ensure that they were free of residual adhesive and cement, which may cause an inflammatory response. The pictures of the recall show that the treatment field has remained completely free of any inflammatory reactions (Fig 11). Both the shade and shape of the restoration blend imperceptibly into the surrounding tooth structure. A healthy gingiva is the best proof of a successful restoration. □

Contact address:

Dr Sandro Pradella
Via Lussemburgo 15
46010 Eremo di Curtatone
Italy
sanpra@tin.it



Shade, form and function

Aesthetic reconstruction with Tetric EvoCeram

Ulf Krueger-Janson, Dentist, Frankfurt/Germany

Modern universal composites have become indispensable materials in today's dental practices. With the introduction of advanced nano-optimized universal composites, the properties and handling of this class of materials has been considerably improved. The following clinical case description demonstrates the advantages of these new materials.

The patient presented to our practice with a fractured tooth (31), which was the result of an accident. We decided to reconstruct the incisal edge with Tetric EvoCeram® using the ExcITE® total-etch adhesive. A transparent acrylic matrix was placed to help shape the restoration.

The matrix band was wrapped around the tooth. It was placed subgingivally in the distal embrasure, since the distal edge did not need to be restored (Fig 1). On the mesial side, however, the matrix was not secured, as it had to be moved to build up the contact point. By keeping the band flexible, we were able to manipulate it as needed.

The matrix band protected the adjacent teeth during the application of the etching gel. When the adhesive (ExcITE) was placed, the matrix was lingually supported with the index finger to prevent it from shifting. This allowed the adhesive to be evenly distributed. For optimum results, the material can be spread into marginal areas with a brush. If the VivaPen delivery form of ExcITE is used, the tip of the pen is ideal for this purpose.

A small amount of Tetric EvoFlow® was placed between the tooth and the matrix to create an initial bubble-free layer that readily adapts to the prepared margins. The composite was smoothed out with a probe (Fig 2). Subsequently, the first opaque layer was applied using Tetric EvoCeram Dentin A3.5. This layer was placed to adjust the intensity of the shade and reflection of the restoration to that of the tooth. In the next step, the mesial walls were re-created by applying more of the composite materials and adapting the matrix.

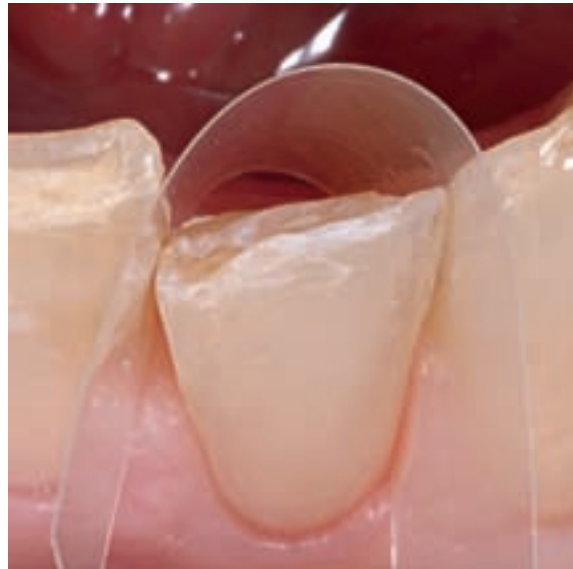


Fig 1 Pre-operative situation: fractured tooth 31 with matrix band in place

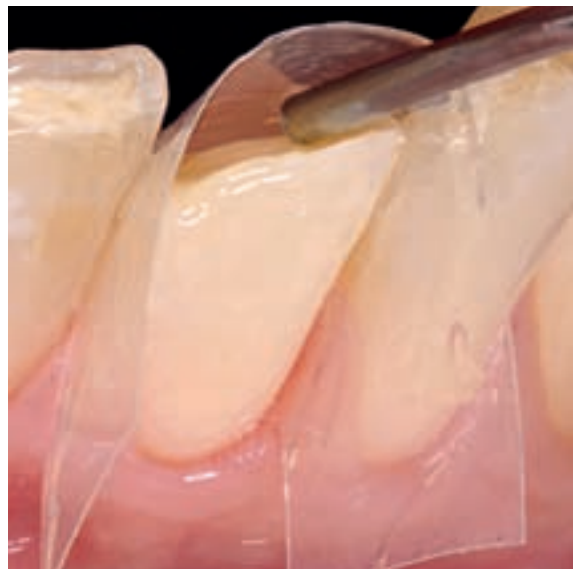

Fig 2 The first restorative layer is neatly adapted to the cavity margins with a probe.

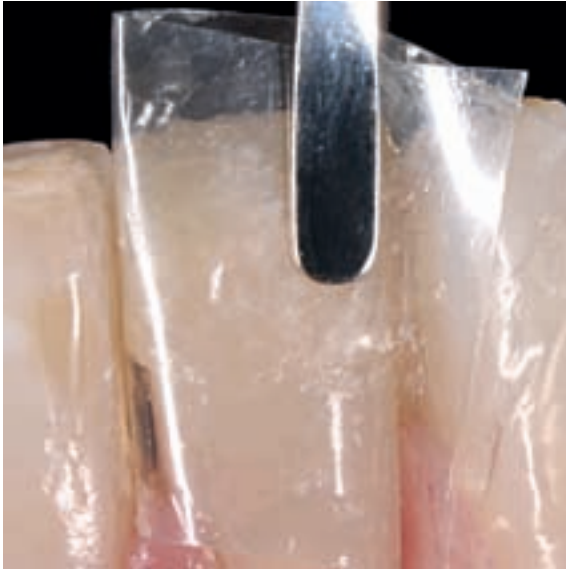

Fig 3 Creation of the contact point

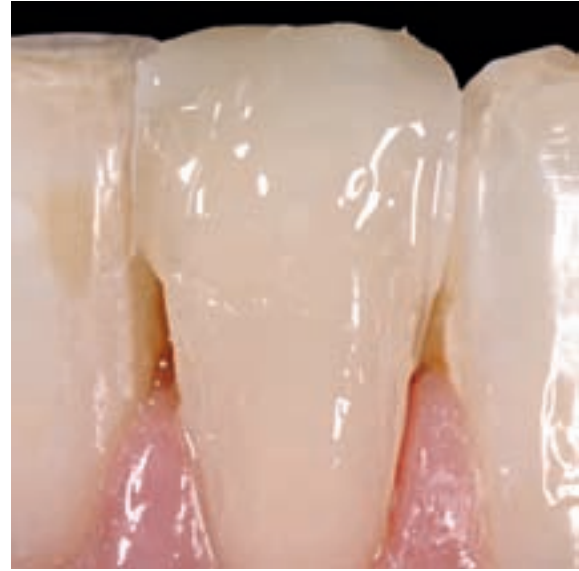

Fig 4 A very light bleached-tooth shade is applied as the final layer.

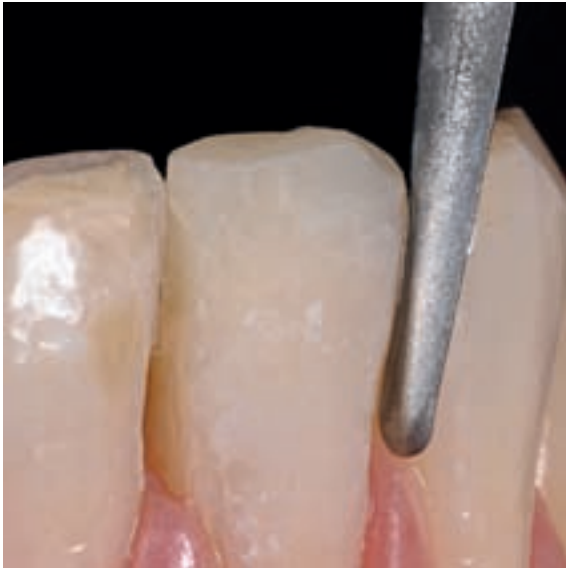

Fig 5 Finishing is carried out with an EVA handpiece.

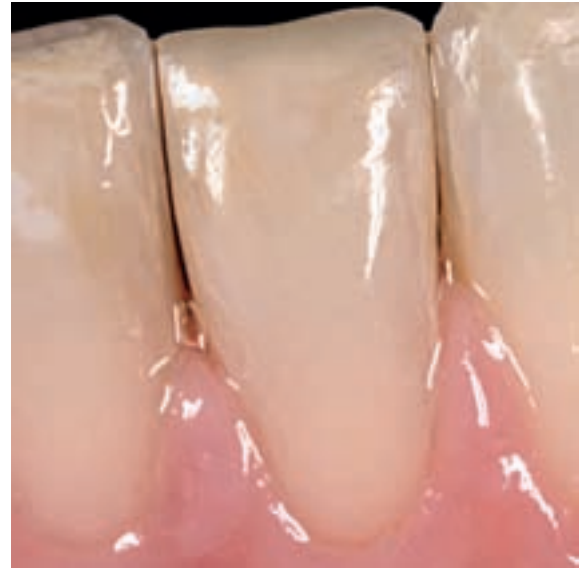

Fig 6 The final picture shows an aesthetic restoration, which smoothly blends into its natural surroundings.

We used a Heidemann spatula to manipulate the material in such a way that we were able to build up a tight contact to the adjacent tooth (Fig 3).

The final layer, which would fully adjust the shade of the restoration to that of the natural tooth structure, was placed using a material that demonstrates brightness and translucency values which corresponded to those of the enamel. In the present case, Bleach L from the Tetric EvoCeram shade system was selected. The material's bright characteristics are clearly visible in Figure 4.

The restoration was finished with an EVA handpiece. A flat-shaped file was used to smooth out the labial surface and remove any grooves. However, a bent file was used to finish the proximal parts of the restoration. The bent part of this file reached into the proximal area and the slight curvature of the insert helped to contour the shape of the restoration in this area (Fig 5).

The remainder of the restoration was finished and the function of the habitual and protrusive positions was checked. The final picture shows the fully restored tooth with a functionally-correct incisal edge (Fig 6). □

Contact address:

Ulf Krueger-Janson, Dentist
Stettenstrasse 48
60322 Frankfurt/Main
Germany
ulf.krueger-janson@t-online.de



Material combination in post build-ups

A case study on the combination of metal and ceramic materials

DDr Marlies Moser and Christoph Zobler, MDT, both based in Innsbruck/Austria

Achieving aesthetically pleasing, structurally sound reconstructions on endodontically treated, devitalized and discoloured teeth in the anterior region often presents a challenge. Functionally difficult cases are susceptible to complications such as fracturing or attachment loss of the post build-up. Against such a background, we have developed a combination of metal and ceramic materials capable of meeting the inherent challenges of such reconstructions.

Case 1: Post with metal-ceramic core build-up and all-ceramic crown

Case history

A 38-year-old female patient presented with inadequate metal-ceramic crowns on tooth 11 and 21. In addition, dark grey staining was observed on tooth 21, which had previously been devitalized and endodontically treated. The patient was concerned about the aesthetic appearance of her anterior teeth. She particularly disliked the discoloured gingiva and the dark triangular gap between her central incisors (Fig 1).

Treatment

Tooth 11 was prepared according to the conventional preparation guidelines for all-ceramic restorations, while the discoloured tooth 21 was prepared with subgingival preparation margins. Post space preparation was followed

by a conventional shoulder preparation (Fig 2). Subsequently, a polysiloxane impression was taken and the preparation was temporized.

Press-on-metal ceramic post – two-part method

The post was cast using a conventional method. The only difference was that the wax-up of the noble alloy post (Callisto® Implant 78) was reduced by approx 0.5 mm to 1 mm to provide space for the ceramic veneering material (Fig 3). The appropriate IPS InLine® PoM opaquer material was applied to the coronal portions of the post and fired. Subsequently, a wax-up of the final post core build-up was fabricated and a sprue was attached (Fig 4). The stump shade of tooth 11 was determined on the patient. Hence, the shade of the IPS InLine PoM post could be accurately matched to the given oral situation and an appropriate

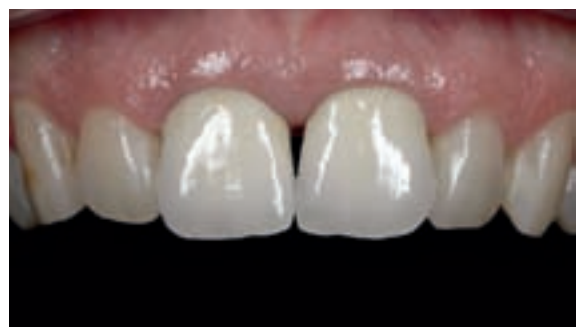

Fig 1 Inappropriate metal-ceramic crowns on teeth 11 and 21

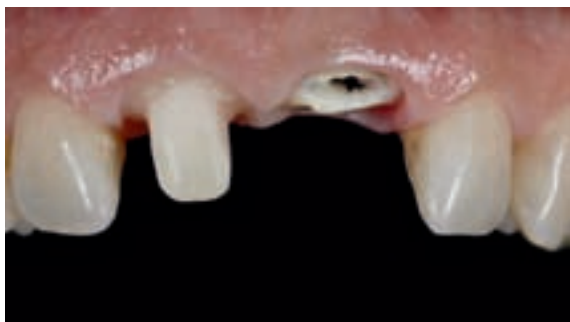

Fig 2 Conventional all-ceramic shoulder preparation

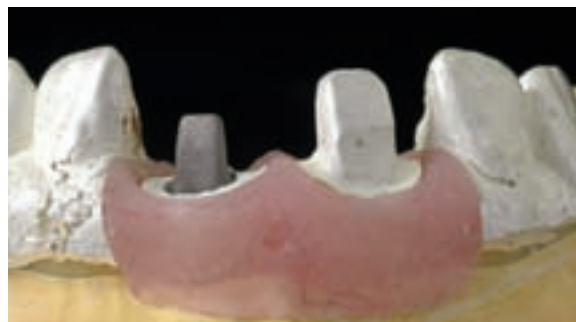

Fig 3 Cast metal post build-up

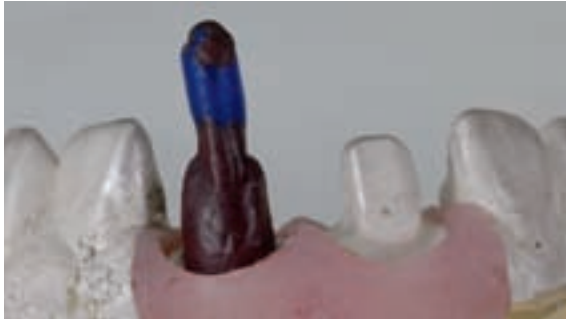

Fig 4 Wax pattern of core build-up with wax sprue

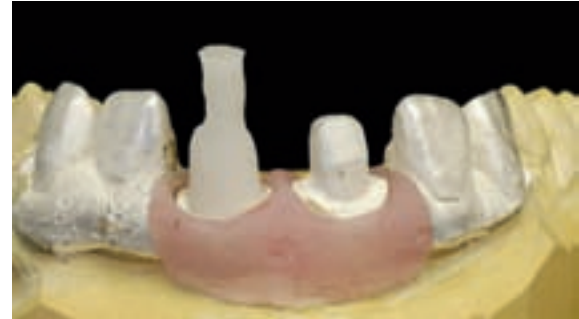

Fig 5 Core build-up after the pressing process with IPS InLine PoM

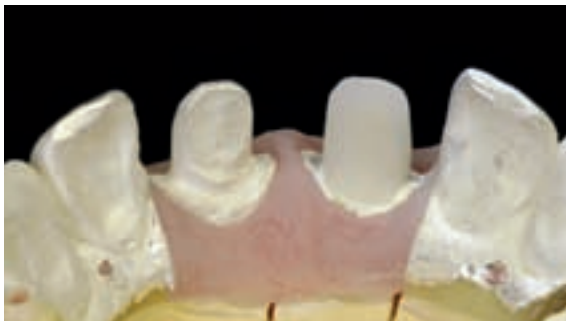

Fig 6 Completed pressed ceramic; ready for etching

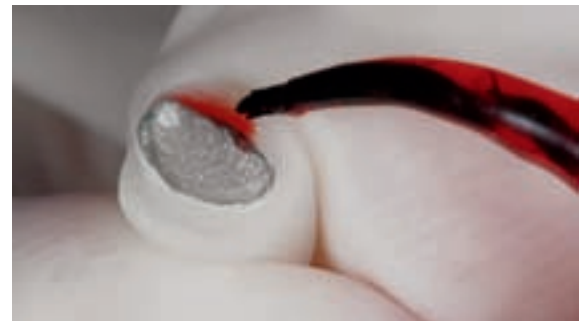

Fig 7 Etching of the metal-ceramic post build-up

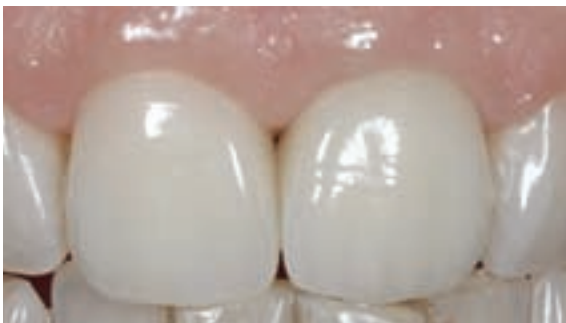

Fig 8 IPS e.max crown surrounded by healthy gingival tissue

ingot could be selected. Upon completion of the press procedure, the post build-up was fitted on the die (Fig 5). The completed pressed ceramic was not glazed. Otherwise, the ceramic could not have been etched. Etching is essential to establish optimal adhesion between the tooth, post and all-ceramic crown (Fig 6).

We decided to use the IPS e.max® Press LT press ceramic to fabricate the crown, as the high strength (400 MPa) and etching capabilities of this material allow an adhesive cementation method and provide a compact bond to the ceramic post.

A fully anatomical crown was pressed, characterized with staining materials and completed with a glaze firing.

In spite of the challenging initial situation (ie vital tooth 11, devitalized tooth 21), both anterior teeth were completed with all-ceramic reconstructions. The combination of the proven gold post method with the press-on ceramic technique resulted in a metal-free restoration as the final finish that closely imitates the dynamic optical properties of the natural tooth structure.

Insertion

After removal of the temporary, the post space was cleaned followed by conditioning with Multilink® A+B. Simultaneously, the ceramic shoulder of the post was etched with hydrofluoric acid (IPS Ceramic Etch Gel) and silanized with Monobond-S, while the metal portion was conditioned with metal primer (Fig 7). The post and post space were coated with Multilink Automix, the post was inserted and excess material was removed. Next, the prepared shoulder on the tooth was etched with phosphoric acid, while the ceramic post build-up was etched with hydrofluoric acid and conditioned with Monobond-S.

Upon completion of this step, the ceramic crowns were inserted using Variolink® II. As soon as four weeks after the insertion, a noticeable improvement of the aesthetics and condition of the gingiva was observed. The restorations were designed in such a way that the black, triangular gap between the incisors was closed and the oxidative deposits at the gingival margins started to disappear. The pictures taken twelve months after the placement show a further improvement of the situation (Fig 8).

Case 2: Crown pressed directly on a post using the press-on-metal technique

Case history

In the present case, a devitalized tooth 41 was treated. This tooth exhibited coronal overfilling and dark greyish discoloration. Reducing the excess coronal root canal filling material and bleaching failed to provide the desired results. Therefore, we decided to implement a post and core reconstruction using a direct press-on-metal crown (Fig 9) rather than using a separate core build-up. This technique is applicable in areas which are aesthetically less prominent.

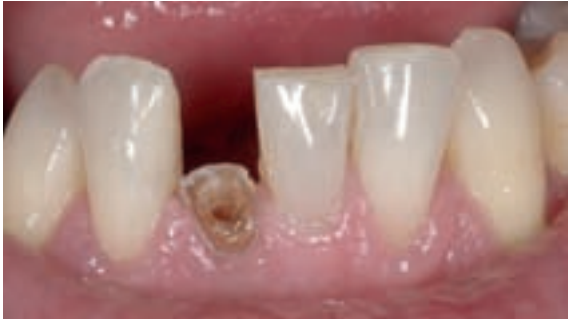

Fig 9 Preparation for a post build-up including a press-on crown

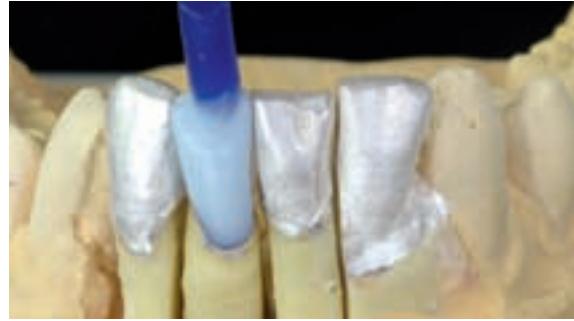


Fig 10 Fully anatomical wax pattern with wax sprue



Fig 11 Crown after characterization and glaze firing

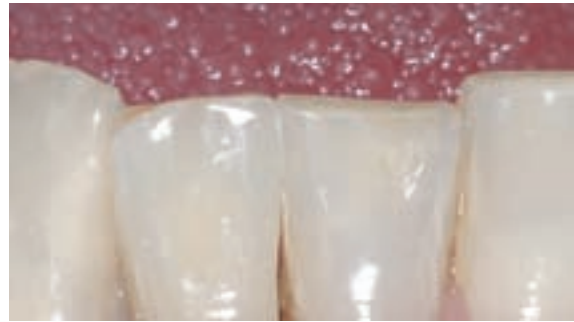

Fig 12 Post crown in situ: the restoration blends harmoniously into the natural surroundings

Treatment

Post and crown preparation was performed following conventional guidelines (see above). The buccal shoulder should be positioned at least as low as the gingival margin to ensure that the dark root sections cannot shine through the restorative material.

Press-on-metal ceramic post – single-part method

A similar procedure as described above was used for the PoM post restoration. The only difference was that a full anatomical wax-up of the exact dimensions of the tooth was created right after the opaquer had been fired, rather than building up a separate core (Fig 10). IPS InLine PoM was utilized for the press-on procedure. The post crown reconstruction was carefully fitted to the die under a microscope. As a circular shoulder was prepared, the impression of an all-ceramic crown was created, even if the substructure of the post core build-up consisted of metal. The restoration was characterized with IPS InLine® Stains and Shade Incisal and completed with a glaze firing (Fig 11).

Insertion

As the post formed an integral part of the dental reconstruction, using a purely chemically curing adhesive composite (Multilink Automix) was indicated for the placement procedure. Dual-curing luting composites fail to provide the desired strength in the deep portions of the preparation, as light cannot penetrate to these areas, which is a drawback. The application procedure of Multilink Automix is the same as that described above. The result is a post crown that harmoniously blends into its natural surroundings (Fig 12).

Conclusions

The above case studies present an elegant route to fabricate aesthetic reconstructions on devitalized anterior teeth,

offering both highly aesthetic results and the stability of proven noble alloy posts. As a cast post is used for the reconstruction, the shape of the root canal is precisely rebuilt. Consequently, the restoration is provided with a retentive component and the adhesive gap along the surface of the entire restoration is minimized. The casting method provides more stability than the application of a conical or round post. Depending on the aesthetic requirements of the given situation, either a two-part (Case 1) or single-part (Case 2) method is used. The two-part method in particular provides highly aesthetic results, as the ceramic core is invisible even when viewed in transmitted light due to the excellent translucent properties of the reconstruction. The single-part method is appropriate for areas that are aesthetically less demanding. Both methods offer the same level of stability. To date, we have fabricated approx. 20 reconstructions using these two methods and none of them has failed. However, long-term results are not yet available, as we only started using these methods twelve months ago. □

Contact address:

DDr Marlies Moser
Südtirolerplatz 1/6
6020 Innsbruck/Austria
praxis@drmoser.eu
www.drmoser.eu

Christoph Zobler, MDT
Inn-Keramik GmbH
Zollerstr. 3
6020 Innsbruck/Austria
info@innkeramik.at
www.innkeramik.com



Composite meets all-ceramic



Restoration of severely worn teeth

Prof Dr Daniel Edelhoff, Munich/Germany and DT Oliver Brix, Wiesbaden/Germany

Modern treatment approaches together with the adhesive bonding technique and state-of-the-art restorative materials enable dental practitioners to significantly reduce the removal of healthy dental hard tissue. This case report describes the complex restoration of several defects in the tooth structure of a young patient using all-ceramic and composite materials. In this case, the patient, dentist and dental technician collaborated very closely in order to draw up a detailed treatment plan which was fastidiously implemented. A wax-up and a diagnostic template as well as modifiable temporary restorations immensely facilitated communication, decision-making and the subsequent preparation work.

Pre-operative situation

A 28-year-old patient wished to improve the appearance of his front teeth. He complained about hypersensitivity while eating. In addition, he had noticed that his teeth were showing increasing wear. In fact, the damage was so severe that the function of the dentition was already impaired (Fig 1).

Treatment plan

Before the treatment plan was finalized, all the old fillings were replaced with composite restorations (Tetric EvoFlow®/Tetric EvoCeram®, Syntac) using the adhesive bonding technique. Furthermore, the severely damaged endodontically treated tooth 11 was built up with a glass-fibre post (FRC Postec® Plus, Variolink®, Syntac). This enabled the treatment team to obtain a clear picture of the size of the defect, the condition of the abutments and the amount of remaining enamel.

After the technical and clinical analysis as well as the evaluation of alternative restorative options, the treatment team and the patient decided on the following treatment plan:

1. Fabrication of an analytical wax-up for the reconstruction of the aesthetics and function as well as for the creation of a diagnostic template

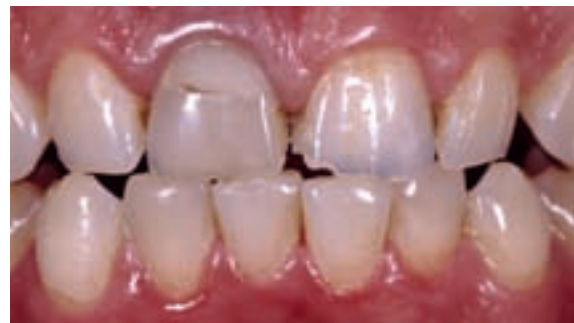

Fig 1 Pre-operative situation: dynamic occlusion

2. Determination of the most suitable restorative materials (direct or indirect) and the corresponding preparation forms
3. Transfer of the information about the required increase of the vertical dimension gained with the wax-up to an occlusal appliance (wearing time of at least four weeks)
4. Preparation of the affected teeth using the diagnostic template as a guide and recording of the maxillo-mandibular relationship (split registration) as well as placement of the temporary restoration fabricated according to the wax-up in one appointment
5. Trial wearing of the temporary restorations and application of any adjustments
6. Impression-taking and prompt lab-fabrication of the restorations
7. Try-in and permanent placement of the all-ceramic restorations
8. Restoration of the lower front teeth with composite materials

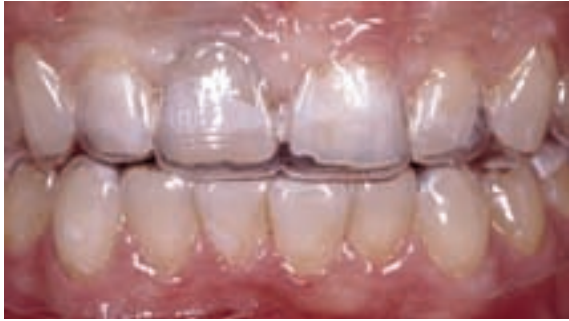

Fig 2 The diagnostic template was tried in to give a first impression of the planned restorative work.

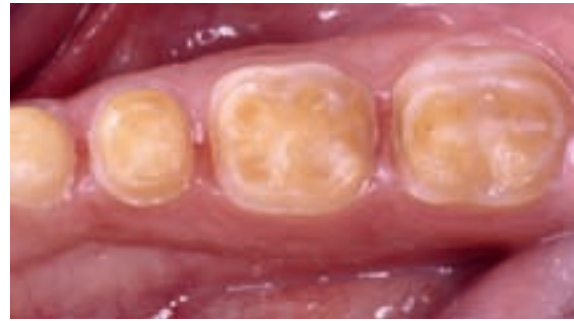

Fig 3 Prepared lower posterior teeth, ready for the glass-ceramic restorations

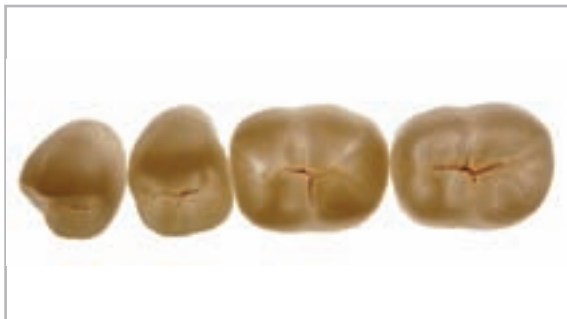

Fig 4 "Tabletops" pressed to full contour with IPS e.max Press HT

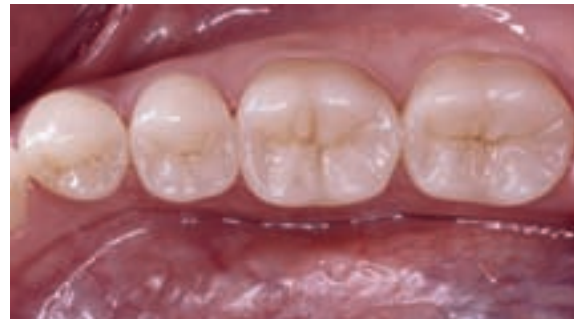

Fig 5 "Tabletops" after adhesive bonding

Preliminary treatment and preparation

The pre-treatment phase started with the patient having to wear an occlusal appliance in the lower jaw for a four-week period. In this step, the vertical dimension was adjusted in accordance with the information gained from the wax-up. The correct relationship between the length and width of the upper anterior teeth was restored.

Furthermore, the diagnostic template which had been fabricated on the basis of the wax-up enabled the patient to obtain a first impression of the treatment goal (Fig 2).

This template served as a guide throughout the treatment and as an orientation aid during the preparation phase. As a result, very little of the tooth structure had to be removed, in accordance with the intended outer contours of the restorations. All the teeth were prepared and the maxillomandibular relationship was recorded in the same appointment. A crown (11) and several veneers had to be placed in the upper anterior jaw. The treatment team decided to use glass-ceramic occlusal veneers (also called "tabletops") to restore the posterior teeth (Figs 3 to 5). All the all-ceramic restorations were fabricated with materials from the IPS e.max® system. The minimum thickness for the pressed lithium disilicate ceramic "tabletops" was defined as 1 mm. These restorations were fabricated with highly translucent ingots (IPS e.max Press HT) using the staining technique.

Temporary restorations

The temporaries were fabricated chairside with the help of the multi-use diagnostic template and a Bis-GMA-based temporary restorative material. In order to enhance the aesthetics of the upper anterior temporaries, a light-curing translucent composite (Tetric EvoCeram®, Shade T) was loaded in the incisal edge area of the template. In the posterior region, the minimally retentive temporary onlays were left splinted. The chairside temporaries were placed with a bonding agent (Heliobond), without prior etching of the tooth structure.

Try-in and incorporation

The restorations were tried in with a tooth-coloured glycerin gel (Try-in Paste, Variolink® II and Variolink® Veneer) to inspect their shape and shade. The marginal seal was examined and the static and dynamic occlusal contacts were carefully checked for the first time with the help of a low-viscosity addition silicone.

Prior to their permanent placement, the inner surfaces of the glass-ceramic restorations were etched with hydrofluoric acid (< 5% IPS Ceramic Etching Gel) for 20 seconds and subsequently conditioned with silane (Monobond-S). The Syntac dentin adhesive system was used on the teeth. The glass-ceramic anterior crown on tooth 11 was seated with a dual-curing, low-viscosity luting composite (Variolink II Base and Variolink II Catalyst, Shade 110). All the veneers and the prepared onlays were placed with either Variolink II Base or

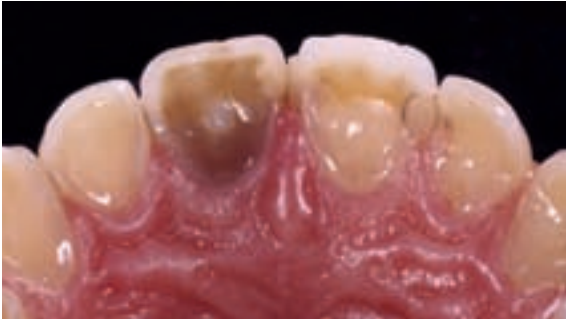

Fig 6 Palatal view of the severely worn upper front teeth (pre-operative situation)

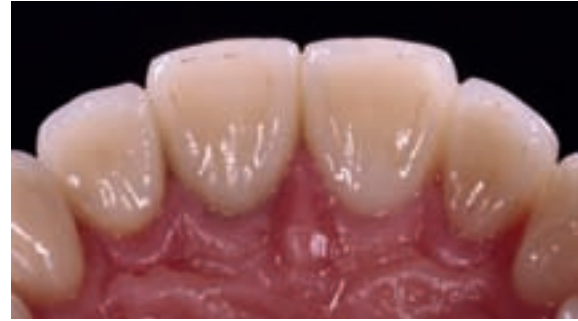

Fig 7 The aesthetic appearance and anterior canine guidance have been restored.

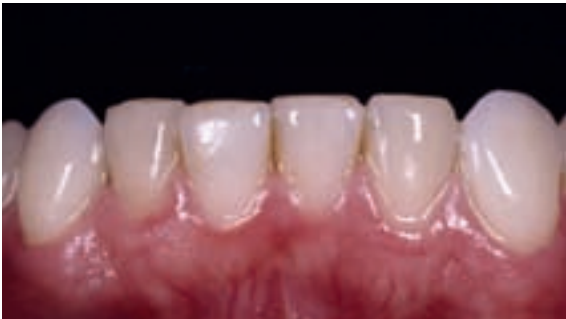

Fig 8 The incisal edges of the lower front teeth show extensive wear. The dentin core is exposed. All the other teeth have already been repaired with glass-ceramic restorations.

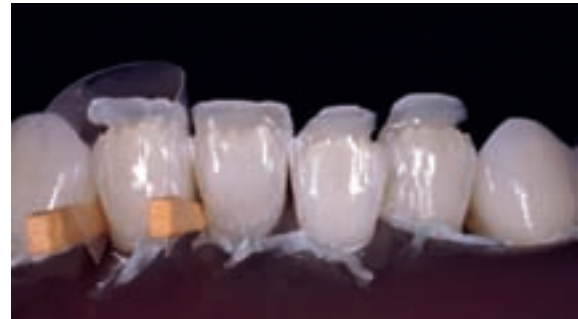

Fig 9 Build-up of the lower front teeth with a composite system that matches the all-ceramic system used. Mamelon-like structures have been incorporated into the existing dental hard tissue to ensure a smooth transition. The lingual contour was transferred from the wax-up with a silicone matrix.

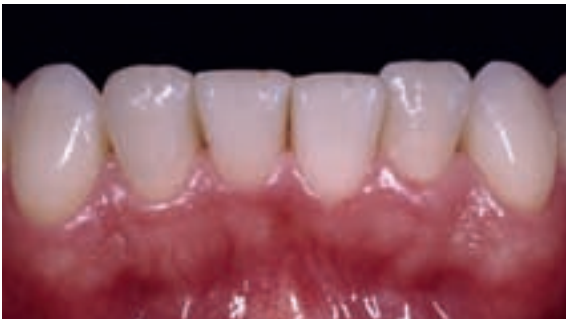

Fig 10 Labial view of the lower front teeth reconstructed with composite after the fine adjustment of the dynamic occlusion and first polish

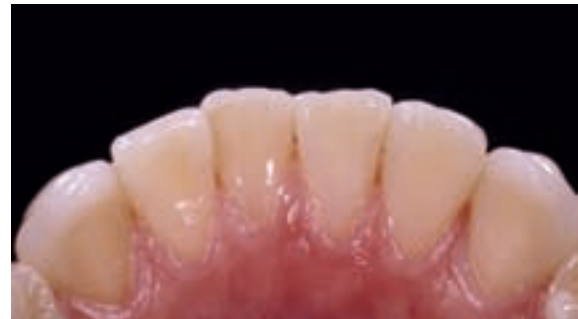

Fig 11 The lingual view of the composite fillings clearly shows the result of the build-up procedure. The transitions to the natural tooth structure are almost invisible.

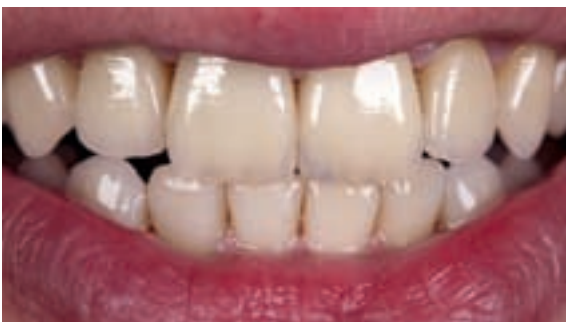

Fig 12 As a result of the adjustment of the tooth length, the smile line is now in harmony with the contours of the lower lip.

anterior teeth were built up with a highly aesthetic matching composite system (Artemis® Professional Set) (Figs 8 to 11). The result of the restorative work fully satisfied the aesthetic expectations of the patient (Fig 12). □

Contact address:

Prof Dr med dent Daniel Edelhoff
Poliklinik fuer Zahnärztliche Prothetik
Ludwig-Maximilians-Universität
Goethestrasse 70
80336 Munich/Germany
daniel.edelhoff@med.uni-muenchen.de

DT Oliver Brix
Innovatives Dental Design
Dwight-D.-Eisenhower-Str 9
65197 Wiesbaden/Germany
oliver-brix@t-online.de

Variolink Veneer and the luting composites were light cured. A high-performance curing light (new bluephase® with > 1200 mW/cm²) was used for the final light-cure (Figs 6 and 7).

After the glass-ceramic restorations had been placed and the fine adjustment of the occlusion made, the lower



Teaming up for the future



IPS AcryCAD – the link between IPS e.max ZirCAD and IPS e.max ZirPress

Volker Brosch, MDT, Essen/Germany

The history of dental technology is a history of rapid developments. Particularly in the areas of technology and materials science, the developments in the past few decades have taken place at a fast and sometimes breakneck pace. Despite these ambitious goals not all the achievements were successes; on several occasions, innovations were pushed forward and introduced prematurely on the market and ended in disastrous failures. Due to the speed with which innovations are being introduced, the failures that have occurred in some cases and the needs of dental technicians for consistency and reliability, reservations about technological developments are widespread.

The foremost precondition for users to embrace technological innovations is that technologies must simplify the work steps and at the same time improve the quality of the restorations. If this requirement is met, innovations are widely accepted, rather than seen as a threat. It is safe to say that the prognosis for new technologies to become a success is good if they contribute to improving quality or if they help to assure quality without demanding too much of the user. This is the only way to combine quality awareness and cost-effectiveness.

Specific materials

Given this backdrop, processing techniques, equipment and materials are closely interlinked. If these components are carefully coordinated by skilled dental technicians, they can minimize risks. The most popular processing technique in our profession is the lost-wax principle. This method is used not only to shape plastic materials and to cast metal, but – for nearly 20 years – also to press dental restorations with ceramic materials. What used to be an absolute innovation at the time has now become routine in the dental laboratory. This has been possible only due to the perfect coordination of the techniques and the corresponding equipment and materials.

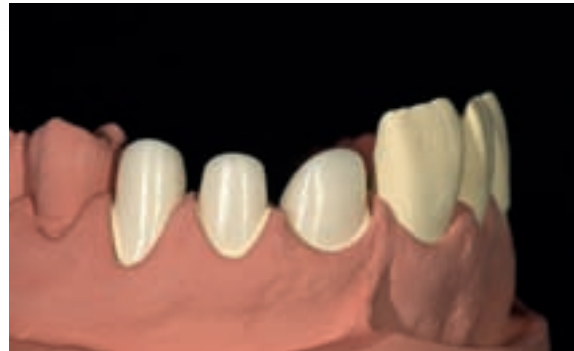

Fig 1 The finished IPS e.max ZirCAD Colour frameworks ...

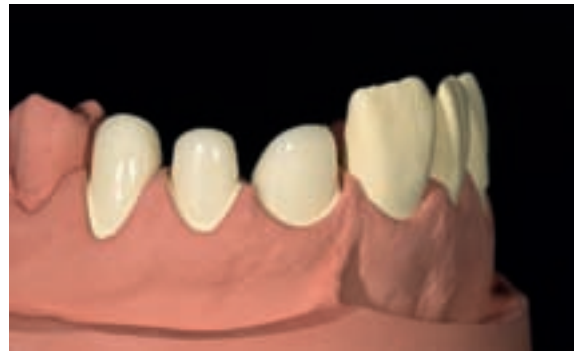

Fig 2 ... are coated with a thin layer of ZirLiner 1.

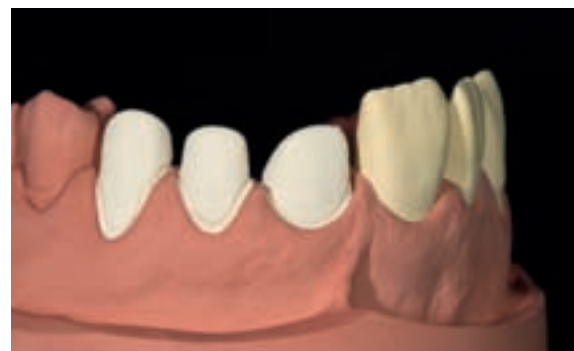

Fig 3 IPS Contrast Spray is applied to prepare the frameworks for the digital scan.



Fig 4 The full-contour part of the canine crown fabricated with IPS AcryCAD

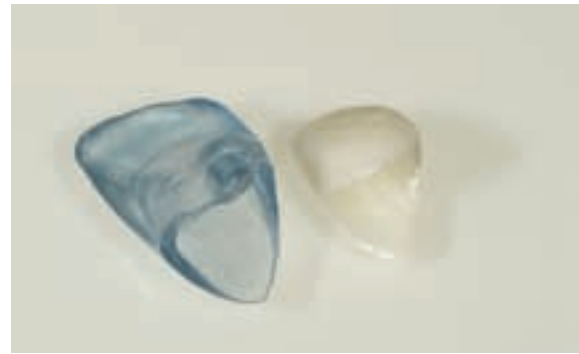

Fig 5 The full-contour resin pattern and zirconium framework ...

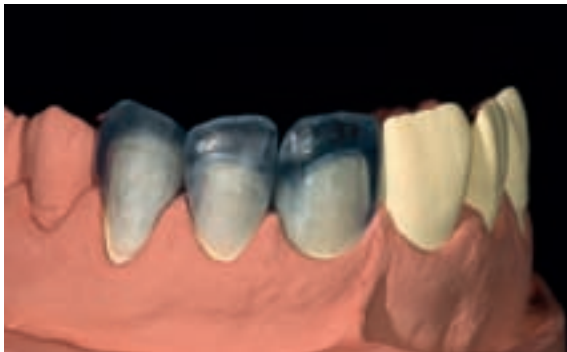

Fig 6 ... are combined to create the shape of the tooth.

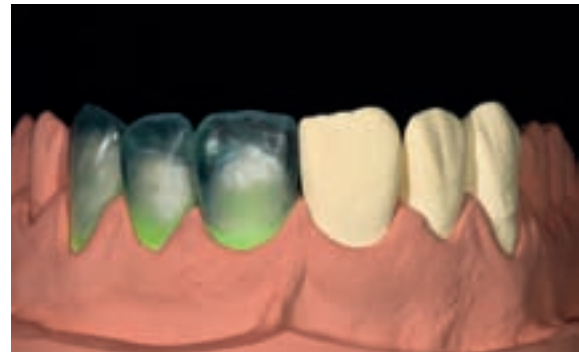


Fig 7 Corrections made with modelling wax complete the model.

Creating synergies

In the development of new dental materials the industry is increasingly focussing on the technological improvements in the field of process engineering. There are an increasing number of exciting new materials that are suitable for processing with CAM systems. The all-ceramic systems IPS Empress® and IPS e.max® can both be pressed and machined. They have recently been complemented by a burn-out resin block (IPS AcryCAD) which can be milled using the CAM technique (Fig 4). IPS AcryCAD links the CAD/CAM technique with the tried-and-tested press and casting technique. This combination offers interesting synergies for the working procedure: For example, zirconium oxide frameworks that have been designed in a CAD program can be used as raw data for the fabrication of full-contour elements that fit onto the frameworks (Figs 1 to 3). A sintered IPS e.max ZirCAD framework and a machine-milled resin model (Fig 5), which can be easily and quickly adapted to the framework, are obtained in this process. Final minor corrections can easily be made by subsequent grinding or by modelling using wax (Figs 6 and 7). If this "sandwich" is then invested and pressed – IPS e.max® ZirPress, a press-on material for zirconium oxide, is pressed into the mould made with IPS AcryCAD – the result is a predominantly digitally fabricated zirconium oxide veneered crown (Figs 8 to 11).

Processing details

First, a framework for the crown or bridge is digitally designed. This framework is then milled using an IPS e.max ZirCAD block. It is finished manually and sintered in a Sintramat. After the sintered framework has been adjusted and coated with a liner, it is scanned again and an anatomical crown or bridge is constructed on it (Fig 3). The CAM machine then mills an IPS AcryCAD block into a crown or bridge (Fig 4). The block is designed in a way that facilitates machine processing. In order to make a visual inspection easier, the see-through material is coloured blue. This allows you to assess the wall thickness visually with only a little practice. As a result, it is easy to control the thickness of the ceramic that is to be pressed onto the framework (Figs 5 to 7).

IPS e.max ZirPress, which is designed for pressing onto zirconium oxide frameworks, is available in three levels of translucency. These levels are adapted to the various applications. The internal translucency of IPS e.max ZirPress LT and HT allows them to be pressed on crowns and bridges to create monochromatic restorations that are subsequently characterized using stains and glaze (Figs 8 to 11). The LT ingots can also be used for the cut-back technique. MO ingots, with their higher opacity, are particularly suitable for pressing a reduced dentin core which is then layered and finished using IPS e.max® Ceram.

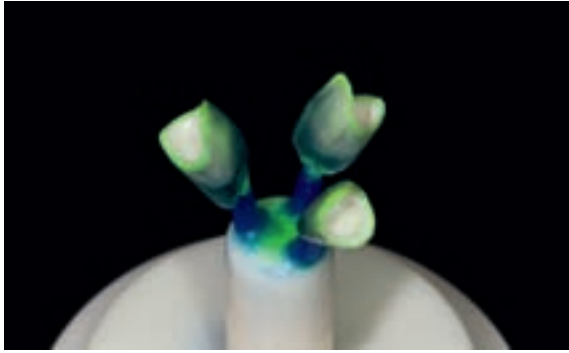


Fig 8 Pressing IPS e.max ZirPress onto zirconium frameworks ...

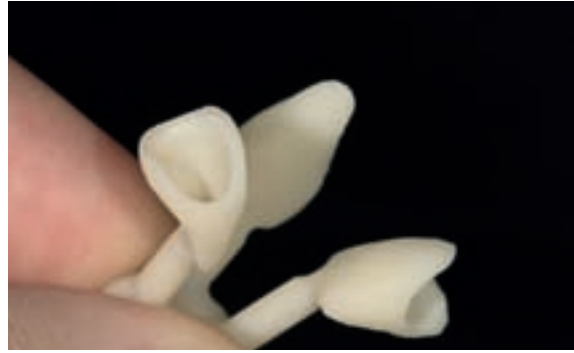

Fig 9 ... is unproblematic.

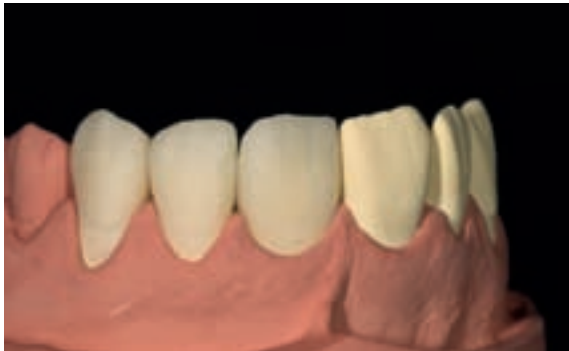

Fig 10 The shape and surface of the crowns have been completed.

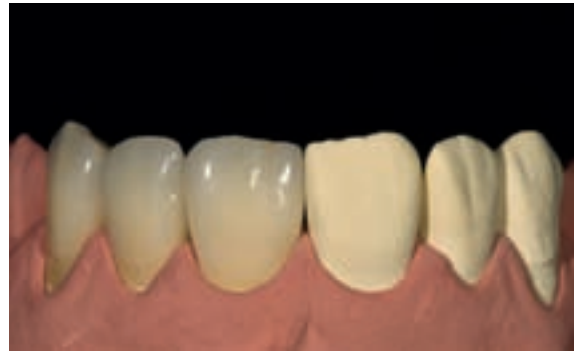

Fig 11 After shading and glazing, the crowns display a very lifelike appearance ...

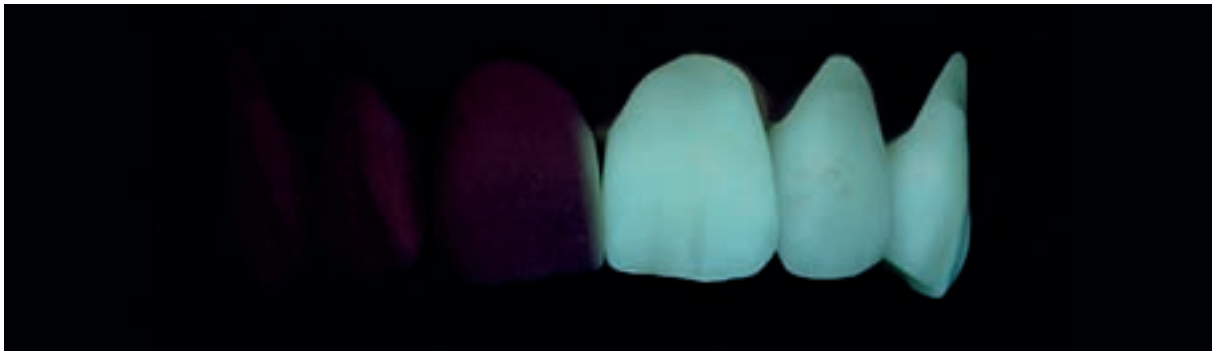


Fig 12 ... and optimum fluorescence.

The perfect harmony of compatible materials, equipment and furnaces offers significant advantages.

CAD/CAM – risk or opportunity?

Increasingly sophisticated products require dental technicians to adjust these innovations to their own needs. Today, we can proceed on the assumption that the CAD/CAM technology and the corresponding products minimize the failure risk and at the same time increase the lab's productivity. □

Contact address:

Volker Brosch, MDT
Brosch Dental
Glühstr. 6
45355 Essen
Germany
info@brosch-dental.de



A new generation of denture teeth

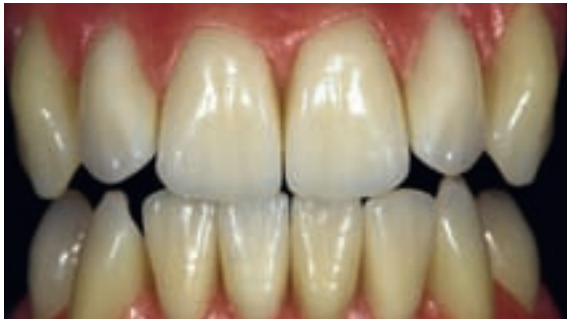The perfect route to aesthetic and functional dentures

Thorsten Michel, MDT, Schorndorf/Germany

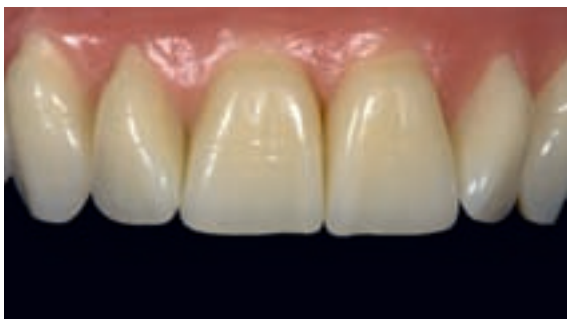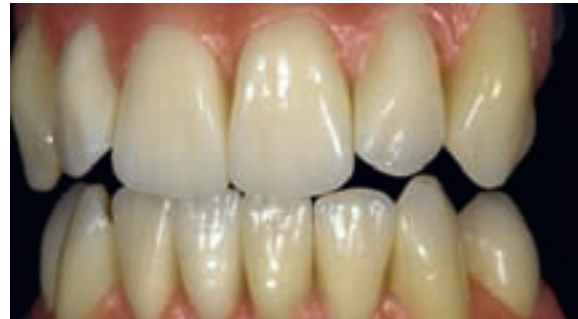In the fabrication of removable dentures at the dental laboratory, I sometimes lack suitable anterior teeth that provide the superior aesthetics very discerning patients demand. Very often, I find myself in the situation of having to modify prefabricated denture teeth, which usually involves the incorporation of age- and indication-related characteristics, to meet the requirements of the individual case.

*I have always considered this situation to be completely unsatisfactory and thus have been constantly on the look-out for a solution to the problem. The purpose of this article is to give a summary of my experiences and provide insight into the development process that led to the creation of the Phonares line of denture teeth.**

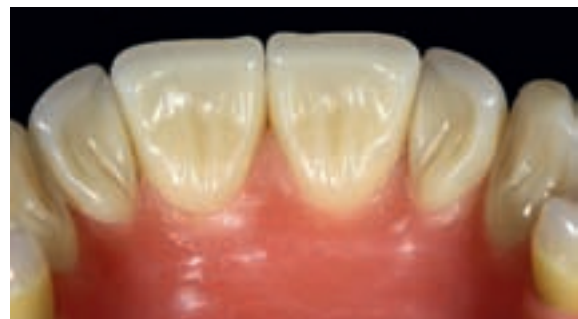I started with modelling upper and lower tooth moulds that were a faithful reflection of their natural counterparts. These moulds featured all the special characteristics that I had previously found missing in existing denture teeth during my everyday work (Figs 1 and 2). For me, it has always been the first impression that counts, in other words the overall aesthetic appearance that is conveyed in the first few seconds in which I view a tooth. These first few seconds are of crucial importance, as this is the time that it takes for me to decide on whether or not the tooth lives up to my expectations. In order to achieve a natural aesthetic outcome, life-like tooth moulds whose facial and palatal surfaces feature a truly anatomical design and impart an impression of naturally grown teeth are essential (Figs 3 to 6).



Figs 1 and 2 Outstanding overall aesthetics of the anterior teeth



Figs 3 and 4 Natural facial and palatal design



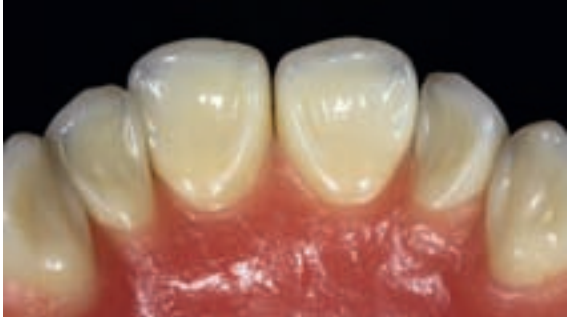

Fig 5 Example of a naturally designed palatal aspect

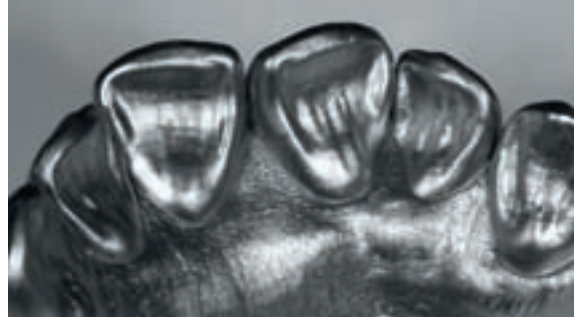

Fig 6 Silver powder discloses details of the exemplary palatal design.

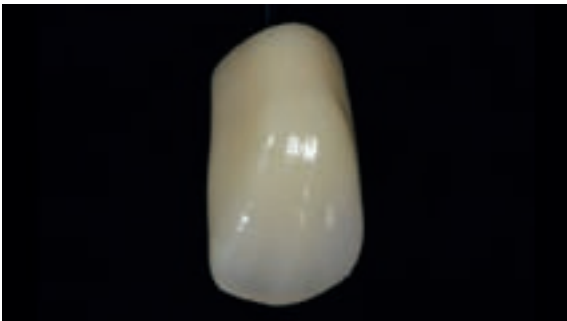

Fig 7 Example of a harmonious layering and a natural-looking opalescent effect



Fig 8 The vibrant facial texture meets the highest aesthetic demands

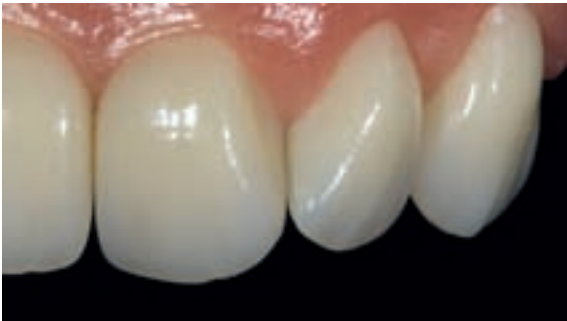

Fig 9 A rounded tooth shape and lighter shades for younger patients

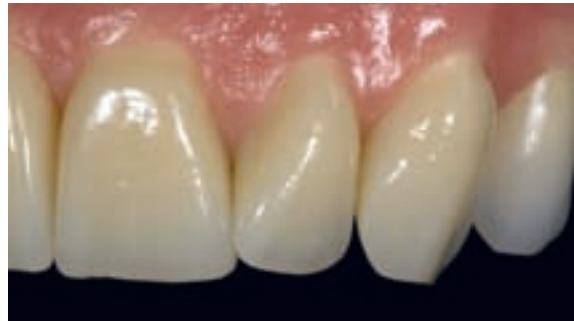

Fig 10 More distinctive tooth moulds and darker shades for patients in the more advanced age group

The objective is to achieve a vibrant, but not overly exaggerated facial texture and a practical palatal and lingual design, which supports clear speech and phonetics rather than hampering it. Moreover, I prefer anterior teeth with a harmonious, layered design and selectively incorporated opalescent and translucent areas that impart them with a life-like appearance (Figs 7 and 8).

A further important aspect for me is to have a logical range of tooth moulds from which to choose. To meet this requirement I tried to incorporate several characteristics into these denture teeth which can also be found in nature. This led to the development of age-related tooth moulds which take the different needs of patients at different stages of life into account. As a result, tooth moulds can be chosen that match the age of the individual patient.

The suitable tooth moulds are selected in three simple steps:

First the basic shape is selected – on the basis of whether the teeth should have a more youthful or distinctive look.

Then the desired degree of wear is chosen. Both the incisal and facial curvature are of importance in this respect. While teeth with more rounded incisal edges and a pronounced facial curvature are designed for use in young patients (Fig 9), those with more heavily abraded incisal edges and a flatter facial curvature are suitable for the more advanced age group (Fig 10). These features are based on the natural ageing process that occurs in the oral cavity over time.

In a third and last step the size, ie the dimension of the tooth is determined by means of the diagnostic cast of the case in question. For this purpose, the teeth are classified into the categories “small”, “medium”, and “large”. Thus tooth moulds for smaller and larger alveolar ridges are available.

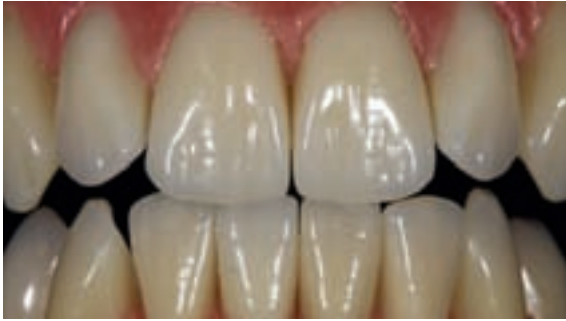

Fig 11 Unparalleled "white aesthetics"

Easy handling is another property I have always valued very highly as a dental technician, in addition to the aesthetic appearance and a sufficiently wide selection of tooth moulds. In these times when everybody is talking about aesthetic dentistry, removable dentures should also provide optimum "white aesthetics" (Fig 11). This is particularly true for implant-borne removable dentures, as all the parties involved, ie the patient, clinician and dental lab technician place high expectations on the aesthetic outcome and function of this complex and expensive type of restoration.

In order to achieve outstanding "white aesthetics", the interproximal contours of anterior teeth should enable the teeth to be lined up very closely without creating the impression of a "white wall".

The proximal "Set & Fit" design which I have developed allows teeth to be set up in the most diverse positions without producing open gingival embrasures that appear as "black triangles" and subsequently need to be filled with denture base material. Even in the case of severely rotated teeth, a natural-looking tooth set-up can be accomplished (Fig 12).

To achieve optimum "white aesthetics", I create a soft transition between the clinical crown and the tooth neck section, as this facilitates modelling of the gingival contours. By placing a wax layer that tapers towards the cervical portion of the clinical crown, the impression of naturally grown gingival tissue is created.

In order to effectively cover or frame construction elements and implant abutments, I created a cervical design which generally accommodates implant abutments with an emergence profile that is approx. 5 mm in diameter. Thus no adjustments with tooth-coloured material are required in the proximal anterior regions in most cases.

Apart from the cutting-edge Phonares anterior tooth design, the teeth are characterized by an extraordinarily high wear resistance as they are made of the new "NHC" (nano-hybrid composite) material. Due to the

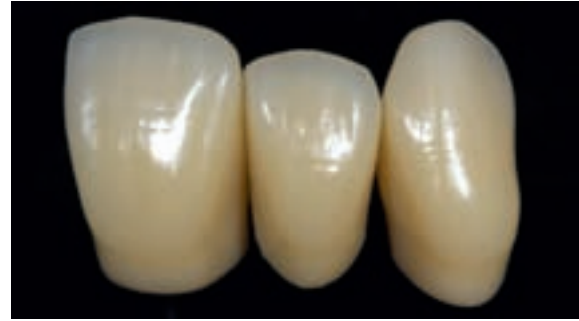

Fig 12 Ideal proximal closure due to the "Set & Fit" design

fact that implants are firmly anchored to the alveolar bone, materials of extremely high strength are required in the fabrication of implant-borne removable dentures. As these dentures are not supported by soft tissue, the masticatory forces are fully transferred to the materials used in the restorative process, so that they are exposed to very high levels of stress.

However, the SR Phonares NHC anterior tooth moulds are not exclusively indicated for implant-borne dentures. They can also be employed in complete and partial denture prosthetics.

Conclusion

A new line of denture teeth has been created which closely replicates the natural dentition in shape and surface texture. The teeth feature a harmonious 4-layer design and have beautiful opalescence and fluorescence. They are made of the new NHC nano-hybrid composite material, which has been proven to provide outstanding wear resistance in various studies. Consequently, high durability and excellent resistance to wear and plaque accretion can be expected. The new denture teeth allow the dental technician to achieve precise, high-quality results with little effort or difficulty.

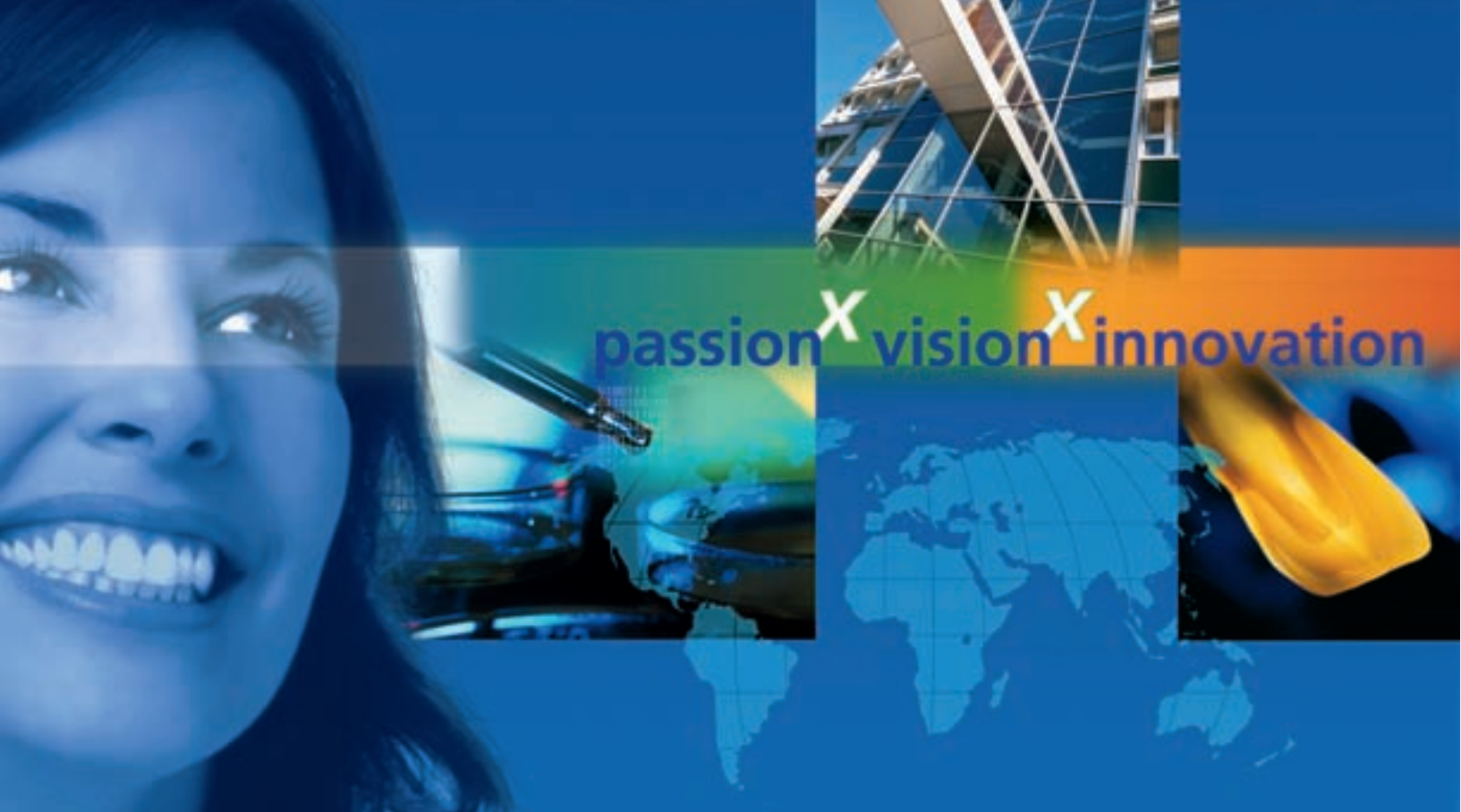The Phonares teeth feature a well-balanced labial and palatal design. Due to the specially designed interdental closures, a natural-looking appearance of the denture is achieved with ease. □

*In the US, the Phonares line of teeth will be available as of July 2009.

Contact address:

Thorsten Michel, MDT
Karlsplatz 2
73614 Schorndorf
Germany
info@michel-zahntechnik.de





Ivoclar Vivadent – worldwide

Liechtenstein

Ivoclar Vivadent AG
Bendererstrasse 2
FL-9494 Schaan
Tél. +423 235 35 35
Fax +423 235 33 60
www.ivoclarvivadent.com

Australia

Ivoclar Vivadent Pty. Ltd.
1 – 5 Overseas Drive
P.O. Box 367
Noble Park, Vic. 3174
Tél. +61 3 979 595 99
Fax +61 3 979 596 45
www.ivoclarvivadent.com.au

Austria

Ivoclar Vivadent GmbH
Bremschstr. 16
Postfach 223, A-6706 Bürs
Tél. +43 5552 624 49
Fax +43 5552 675 15
www.ivoclarvivadent.com

Brazil

Ivoclar Vivadent Ltda.
Rua Geraldo Flausino Gomes,
78 – 6.º andar Cjs. 61/62
Bairro: Brooklin Novo
CEP: 04575-060 São Paulo – SP
Tél. +55(11) 3466 0800
Fax. +55(11) 3466 0840
www.ivoclarvivadent.com.br

Canada

Ivoclar Vivadent Inc.
2785 Skymark Avenue, Unit 1
Mississauga, Ontario L4W 4Y3
Tél. +1 905 238 57 00
Fax +1 905 238 57 /11
www.ivoclarvivadent.us

China

Ivoclar Vivadent Marketing Ltd.
Rm 603 Kuen Yang
International Business Plaza
No. 798 Zhao Jia Bang Road
Shanghai 200030
Tél. +86 21 5456 0776
Fax. +86 21 6445 1561
www.ivoclarvivadent.com

Colombia

Ivoclar Vivadent Marketing Ltd.
Calle 134 No. 7-B-83, Of. 520
Bogotá
Tél. +57 1 627 33 99
Fax +57 1 633 16 63
www.ivoclarvivadent.com

France

Ivoclar Vivadent SAS
B.P. 118
F-74410 Saint-Jorioz
Tél. +33 450 88 64 00
Fax +33 450 68 91 52
www.ivoclarvivadent.fr

Germany

Ivoclar Vivadent GmbH
Dr. Adolf-Schneider-Str. 2
D-73479 Ellwangen, Jagst
Tél. +49 (0) 79 61 / 8 89-0
Fax +49 (0) 79 61 / 63 26
www.ivoclarvivadent.de

India

Ivoclar Vivadent Marketing Ltd
(Liasion Office)
503/504 Raheja Plaza
15 B Shah Industrial Estate
Veera Desai Road, Andheri (West)
Mumbai , 400 053
Tél. +91 (22) 2673 0302
Fax. +91 (22) 2673 0301
www.ivoclarvivadent.com

Italy

Ivoclar Vivadent s.r.l. & C. s.a.s
Via Gustav Flora, 32
39025 Naturno (BZ)
Tél. +39 0473 67 01 11
Fax +39 0473 66 77 80
www.ivoclarvivadent.it

Japan

Ivoclar Vivadent K.K.
1-28-24-4F Hongo
Bunkyo-ku
Tokyo 113-0033
Tél. +813 6903 3535
Fax +813 5844 3657
www.ivoclarvivadent.jp

Mexico

Ivoclar Vivadent S.A. de C.V.
Av. Mazatlán No. 61, Piso 2
Col. Condesa, 06170 México, D.F.
Tél. +52 (55) 5062-1000
Fax +52 (55) 5062-1029
www.ivoclarvivadent.com.mx

New Zealand

Ivoclar Vivadent Ltd
12 Omega St, Albany
PO Box 5243 Wellesley St
Auckland
Tél. +64 9 914 99 99
Fax +64 9 914 99 90
www.ivoclarvivadent.co.nz

Poland

Ivoclar Vivadent Polska Sp. z o.o.
ul. Jana Pawla II 78
PL-00175 Warszawa
Tél. +48 22 635 54 96
Fax +48 22 635 54 69
www.ivoclarvivadent.pl

Russia

Ivoclar Vivadent Marketing Ltd.
Derbenevskaja Nabereshnaya 11
Geb. W, 115114 Moscow
Tél. +7 495 913 66 19
Fax +7 495 913 66 15
www.ivoclarvivadent.ru

Singapore

Ivoclar Vivadent Marketing Ltd.
171 Chin Swee Road
#02-01 San Centre
Singapore 169877
Tél. +65-6535 6775
Fax +65-6535-4991
www.ivoclarvivadent.com

Spain

Ivoclar Vivadent S.L.U.
c/Emilio Muñoz Nº 15
Entrada c/Albarracín
E-28037 Madrid
Tél. +34 91 375 78 20
Fax +34 91 375 78 38
www.ivoclarvivadent.es

Sweden

Ivoclar Vivadent AB
Dalvägen 14, S-169 56 Solna
Tél. +46 08 514 93 930
Fax +46 08 514 93 940
www.ivoclarvivadent.se

Turkey

Ivoclar Vivadent Liaison Office
Ahi Evran Caddesi no 1
Polaris Is Merkezi Kat: 7
80670 Maslak
Istanbul
Tél. +90 212 346 04 04
Fax +90 212 346 04 24
www.ivoclarvivadent.com

United Kingdom

Ivoclar Vivadent UK Limited
Ground Floor Compass Building
Feldspar Close
Warrens Business Park
Enderby
Leicester LE19 4SE
Tél. +44 116 284 78 80
Fax +44 116 284 78 81
www.ivoclarvivadent.com

USA

Ivoclar Vivadent, Inc.
175 Pineview Drive
Amherst, N.Y. 14228
Tél. +1 800 533 6825
Fax +1 716 691 2285
www.ivoclarvivadent.us

ivoclar
vivadent
passion vision innovation